BREAST IMAGING

DR VALENTINA OPANCINA, MD, PHD

ASSOCIATE PROFESSOR

DEPARTMENT OF RADIOLOGY, FACULTY OF MEDICAL SCIENCES, UNIVERSITY OF KRAGUJEVAC

УНИВЕРЗИТЕТ
У КРАГУЈЕВЦУ

Objectives

- Ro examination modalities and techniques,
- Ro and US anatomy of the breast,
- Benign and malignant changes

Terminal ductal lobular unit

- The terminal ductal lobular unit is an important structure because most invasive cancers arise from the TDLU.
- It also is the site of origin of ductal carcinoma in situ (DCIS), lobular carcinoma in situ, fibroadenoma and fibrocystic disease, like cysts, apocine metaplasia, adenosis and epitheliosis.
- Most calcifications in the breast form either within the terminal ducts (intraductal calcifications) or within the acini (lobular calcifications).

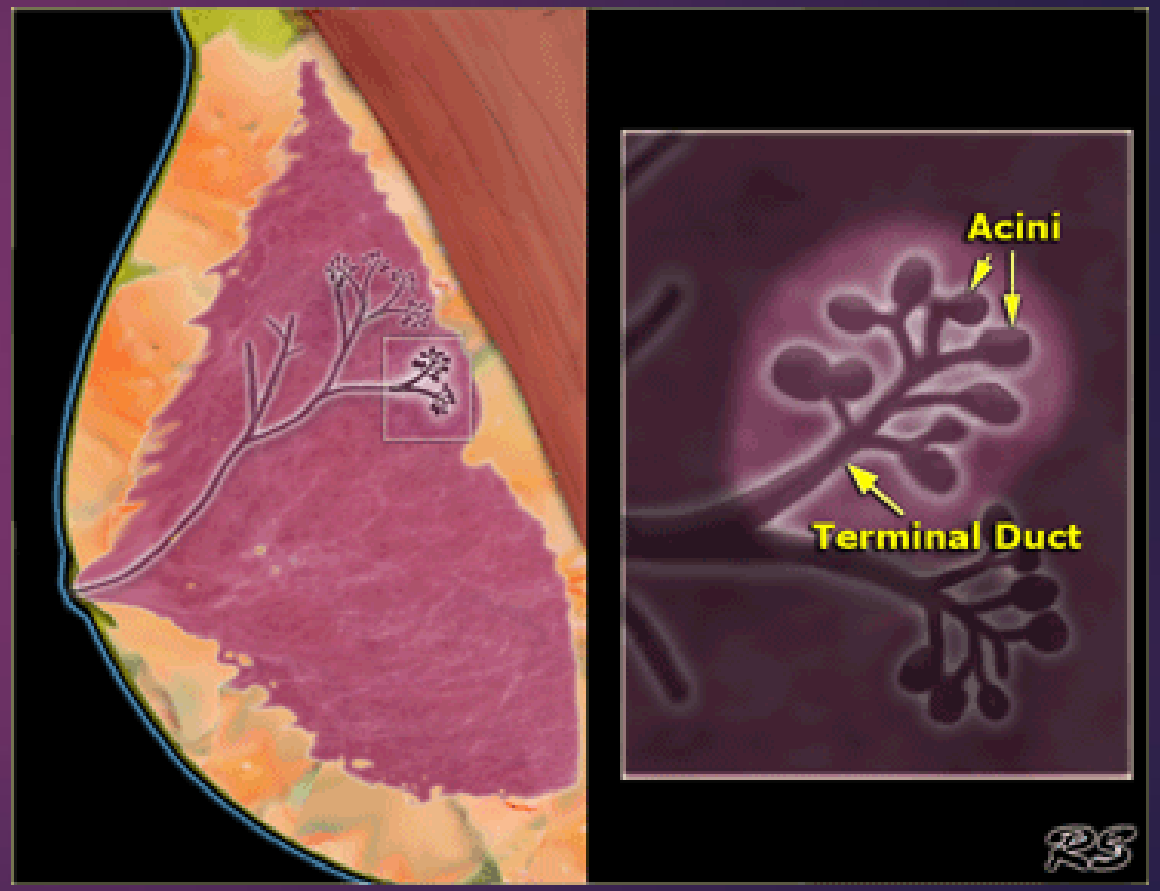

Methods of detection of breast cancer:

Breast Self Examination

Clinical Breast Exam

Breast ultrasound

Mammography

Breast ultrasound

Use of breast ultrasound:

- evaluate young (usually under 30 years of age) or pregnant patients who are symptomatic
- evaluate a palpable lump with negative or equivocal mammographic findings
- detect lesions in lower contrast field
- help to distinguish between benign vs malignant characteristics
- guiding biopsy
- evaluate breast implants for rupture

What women are referred for breast imaging?

Two groups of women are referred for breast imaging, those without symptoms (asymptomatic) and those with symptoms.

The asymptomatic women have a screening mammogram to look for small nonpalpable abnormalities in the breasts.

Mammography

- **Mammography** is a dedicated radiographic technique for imaging the breast.
- **Types of mammography**
- In general terms, there are two types of mammography: screening and diagnostic.
- Mammography differs significantly in many respects from the rest of diagnostic imaging.

Screening mammography

- In general terms, screening mammography is performed on asymptomatic women to identify malignant breast pathology at an early, potentially curable stage.
- Regardless of confusing statistics in lay publications, the earlier breast cancer is picked up, all other factors being equal, the better the survival rate. Screening mammography is performed on clients, not patients.

Breast Cancer: Why Screen?

- Improved outcome by treatment during the asymptomatic period
- Significant impact on public health

Diagnostic mammography

- Imaging performed on symptomatic patients, or to work-up an abnormality found on screening mammography.
- The objective is to use imaging to typify pathology and arrive at a diagnosis. This is important because different diagnoses have significantly different outcomes and survival rates.
- For instance, a diagnosis of a simple breast cyst has few implications and does not affect the patient's life expectancy.
- In contrast, a diagnosis of breast cancer has significant implications for the patient and her life expectancy.

Digital mammography

- Quicker to do mammo – almost instant output on monitor
- Better penetration of dense breast
- Digital manipulation of image

Digital mammography

- Proven to be better for younger/denser breasts
- Almost eliminates the need for magnification views – can magnify digitally and still have full resolution

American College of Radiology Recommendations for Imaging Screening for Breast Cancer

- **Women at average risk for breast cancer**
  - Annual screening from age 40

- **Women at increased risk for breast cancer**

1. Women with certain *BRCA1* or *BRCA2* mutations or who are untested but have first-degree relatives (mothers, sisters, or daughters) who are proved to have *BRCA* mutations
   - ■Yearly starting by age **30 (but not before age 25)**

American College of Radiology Recommendations for Imaging Screening for Breast Cancer

2. Women with ≥20% lifetime risk for breast cancer on the basis of family history (both maternal and paternal) and Women with mothers or sisters with pre-menopausal breast cancer

- Yearly starting by age 30 (but not before age 25), or 10 years earlier than the age of diagnosis of the youngest affected relative, whichever is later

American College of Radiology Recommendations for Imaging Screening for Breast Cancer

3. Women with histories of mantle radiation (usually for Hodgkin's disease) received between the ages of 10 and 30.

- Yearly starting 8 years after the radiation therapy, but not before age 25.

American College of Radiology Recommendations for Imaging Screening for Breast Cancer

4. Women with biopsy-proven lobular neoplasia (lobular carcinoma in situ and atypical lobular hyperplasia), atypical ductal hyperplasia (ADH), ductal carcinoma in situ (DCIS), invasive breast cancer or ovarian cancer

- Yearly from time of diagnosis, regardless of age.

- ***Age at Which Annual Screening With Mammography Should Stop.***

- When life expectancy is <5 to 7 years on the basis of age or comorbid conditions

- When abnormal results of screening would not be acted on because of age or comorbid conditions

INDICATIONS

- Breast Cancer.
- Breast Lump.
- Nipple Discharge.
- Focal Breast Pain.
- Follow up for previously evaluated Mammographic findings.
- BIRADS (Breast Imaging Reporting and Detection System).

CONTRAINDICATIONS

- Size of cancer relative to Breast Size.
- First or Second-trimester pregnancy.
- Prior radiation therapy to chest/mediastinal.
- Active Collagen Vascular disease.

Mammography

- **Principle:** Breast is composed of fatty tissue, glandular tissue, and connective tissue.
- Normal and cancerous tissues in the breast have small x-ray attenuation differences between them
- Need x-ray equipment specifically designed to optimize breast cancer detection.

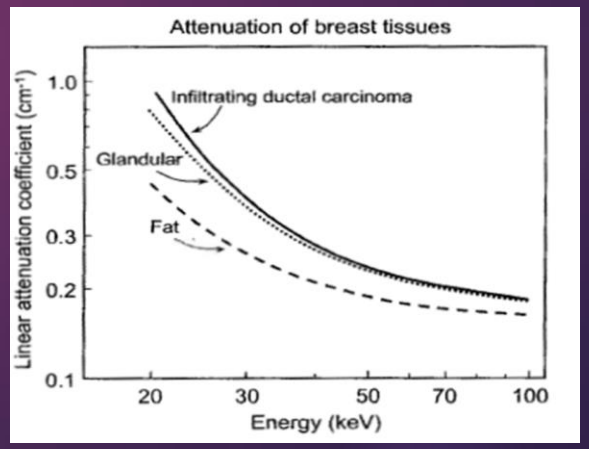

Modern Equipment

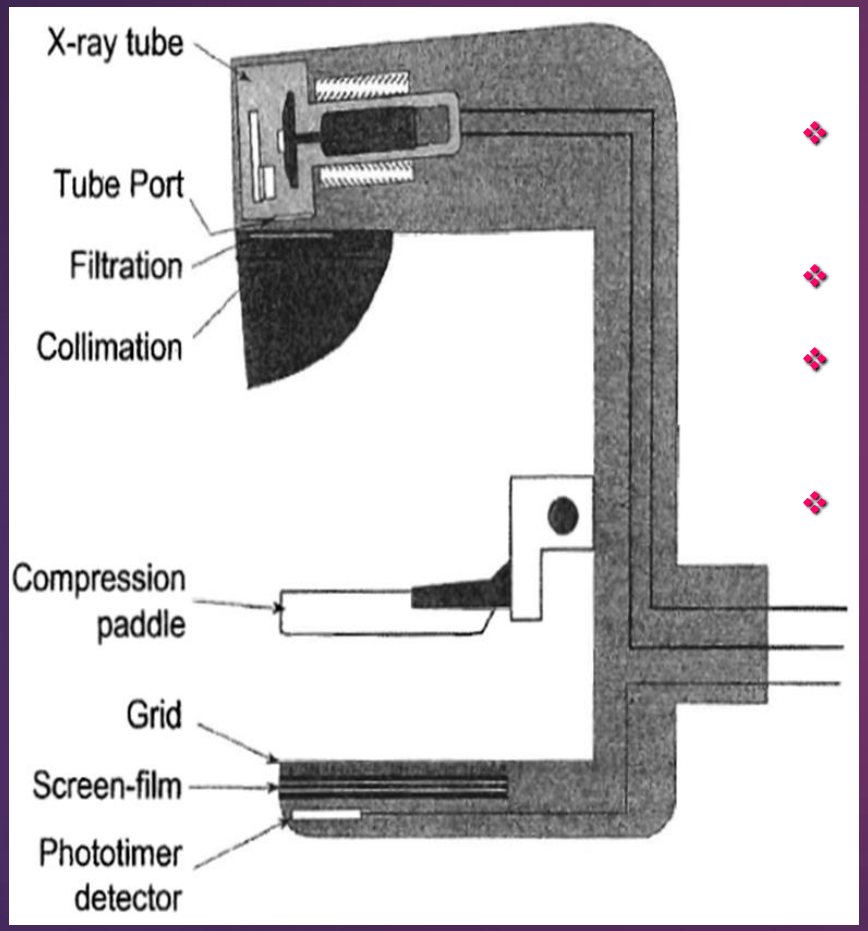

- Dedicated Mammography Equipment
- Specialized X-ray Tubes
- Optimized Screen/Film detector systems
- Breast Compression Devices

MAMOGRAPHY POSITIONING

- Bring the breast back to its true anatomical position.
- Use palpable and anatomical landmarks for positioning and clinical image evaluation.
- It should be consistent and Reproducible with the goal of maintaining improving quality.

The craniocaudal view

- It includes maximum amount of breast tissue in axial plane.
- Visualization of medial breast tissue (Cleavage).
- Visualization of pectoralis muscle on approximately 30% of all CCs.

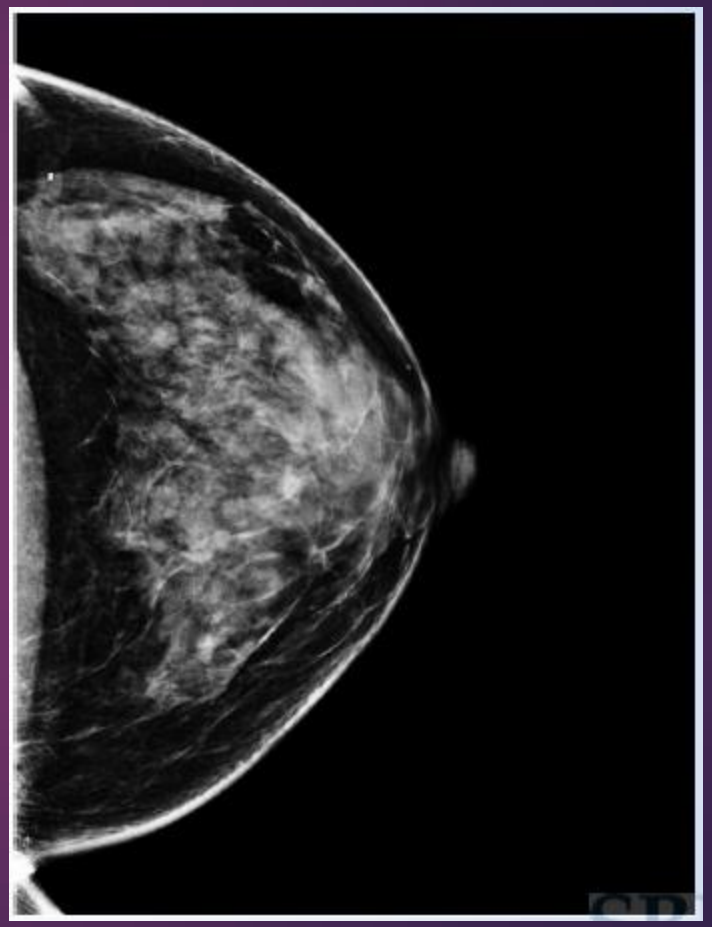

MEDIO LATERAL OBLIQUE

- Inclusion of all the breast tissue within perimeter.
- Pectoralis muscle fully visualized.
- Tissue well separated.
- Tissue visualized back to retro-mammary fat space.
- IMF.

MLO

POSITION:

- C-arm of the unit is rotated to 45 angle, so that the cassette is parallel to pectoral muscle.
- The film holder is kept high in axillary fossa.
- Arm is abducted at elbow.

Adequate craniocaudal (CC) views:

- all glandular tissue identified
- nipple in profile
- nipple in the midline of image
- length of posterior nipple line (PNL) within one 1 cm in size c.f PNL on MLO
- images symmetric

Adequate mediolateral oblique (MLO) views:

- pectoral shadow is seen down to the level of the nipple or lower
- inframammary fold is well seen
- nipple in profile
- length of posterior nipple line (PNL) within one 1 cm in size c.f PNL on CC
- images symmetric

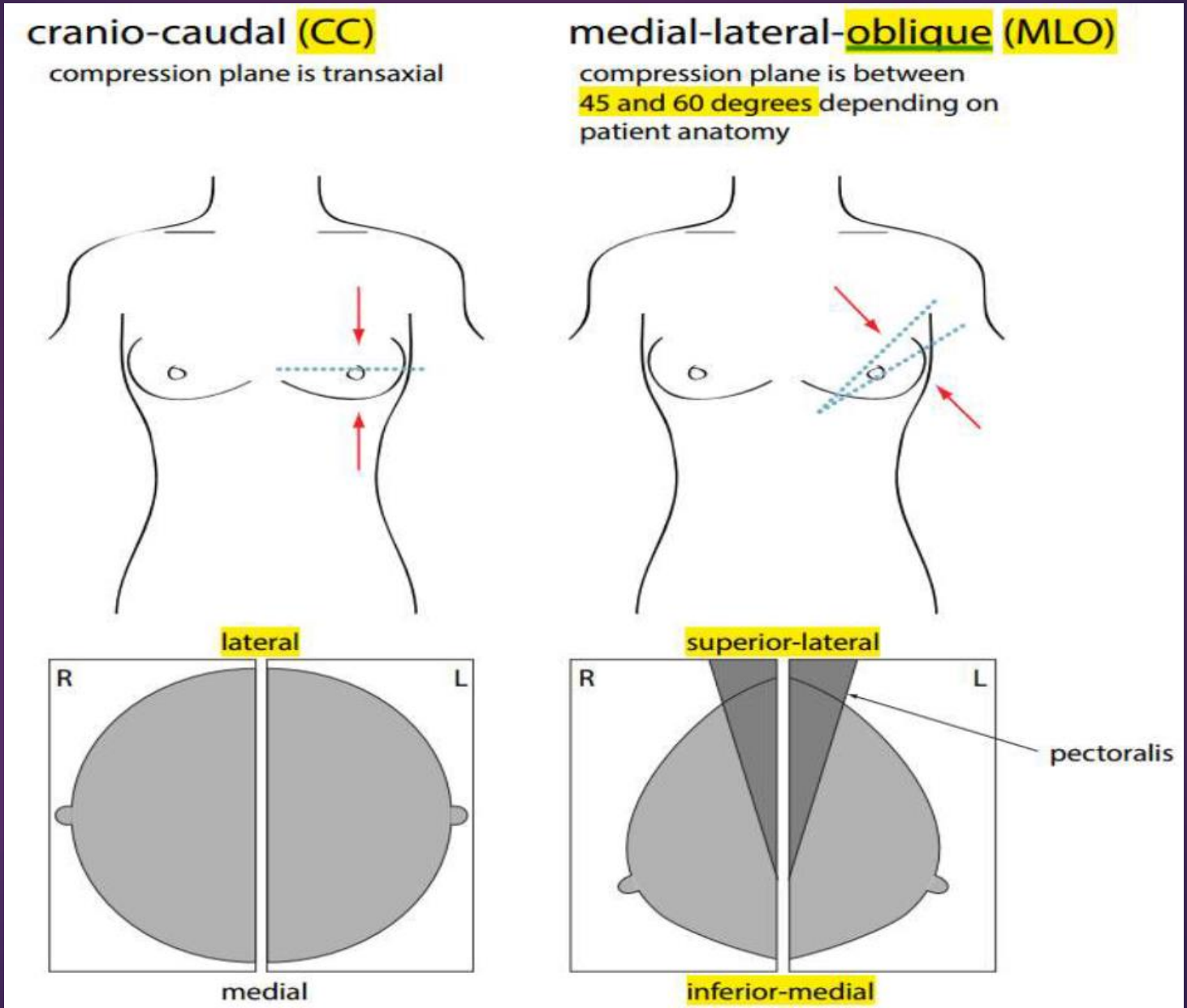
cranio-caudal (CC)
compression plane is transaxial
medial-lateral-oblique (MLO)
compression plane is between 45 and 60 degrees depending on patient anatomy
lateral
R
L
medial
superior-lateral
R
L
pectoralis
inferior-medial

Normal findings

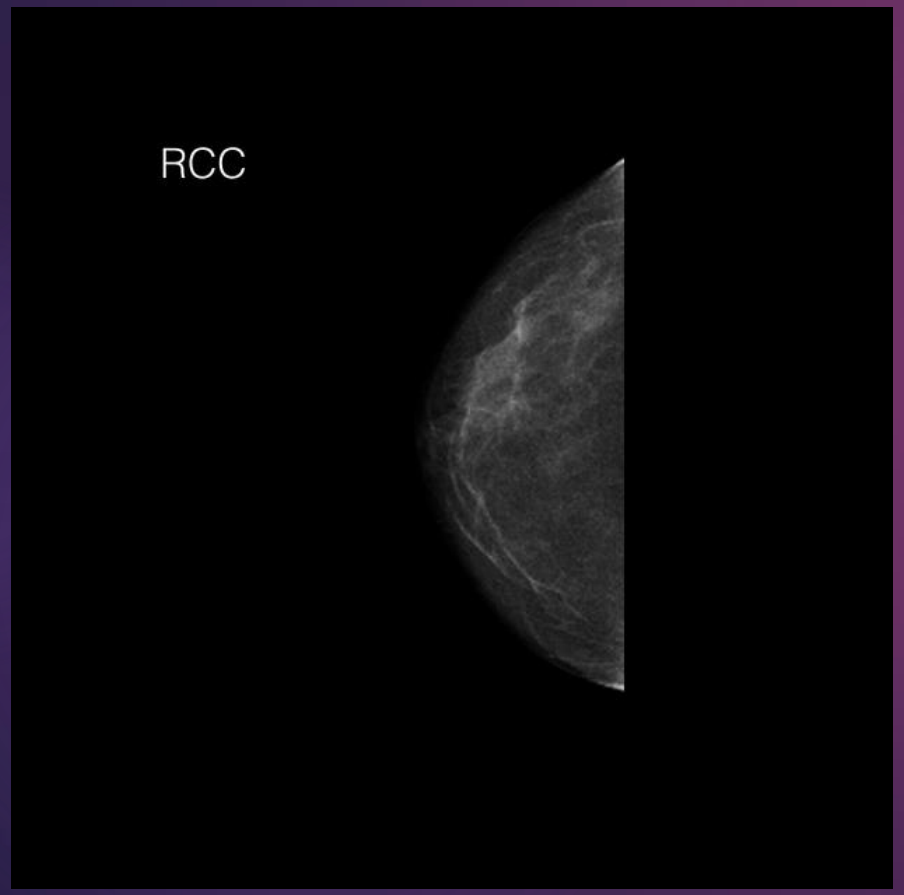

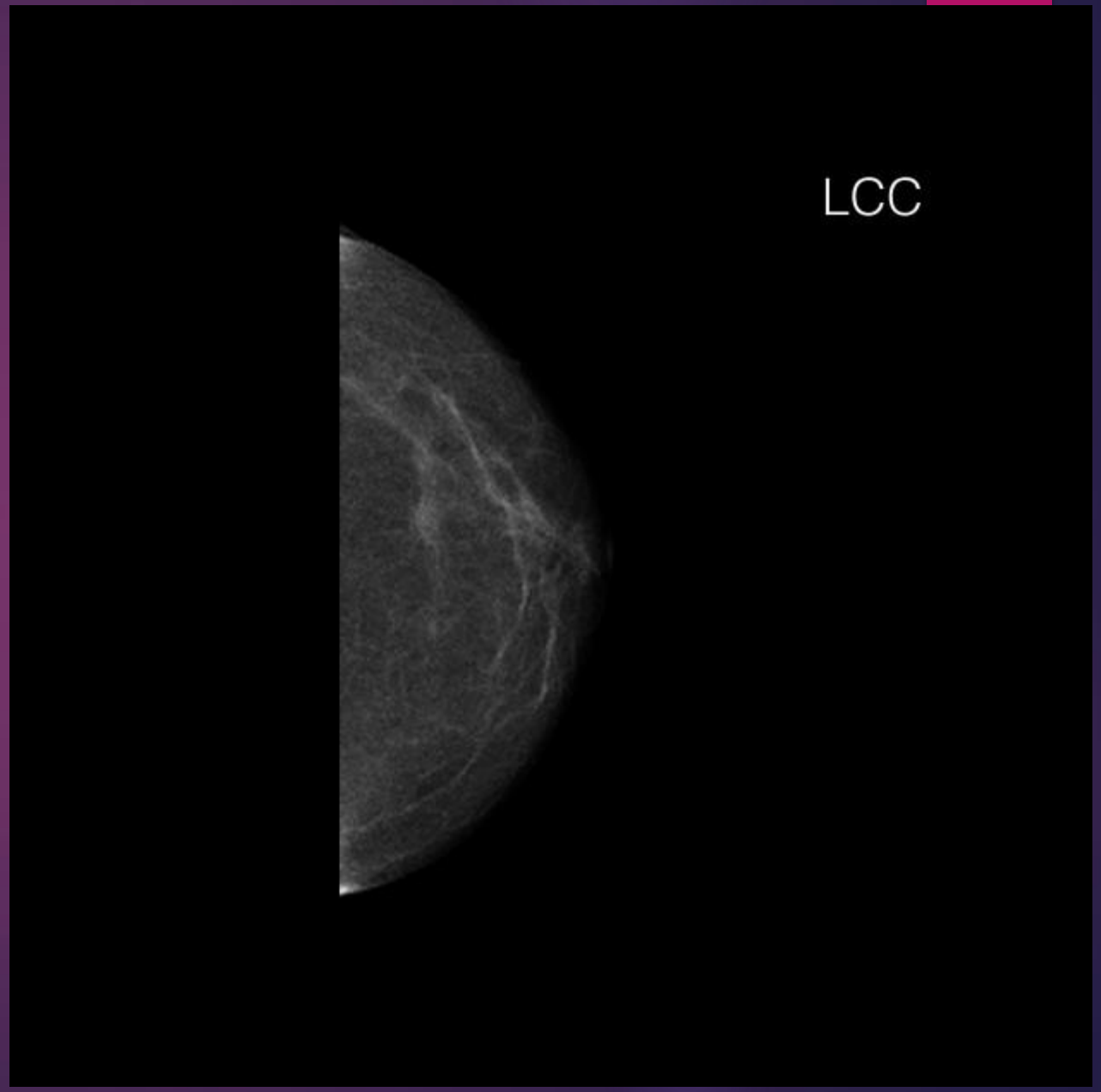

Breast imaging-reporting and data system (BI-RADS)

- **BI-RADS** (**Breast Imaging-Reporting and Data System**) is a risk assessment and quality assurance tool developed by American College of Radiology that provides a widely accepted lexicon and reporting schema for imaging of the breast. It applies to mammography, ultrasound, and MRI.

Classification

- Breast imaging studies are assigned one of seven assessment categories:
- BI-RADS 0: incomplete
  - need additional imaging evaluation (additional mammographic views or ultrasound) and/or for mammography, obtaining previous images not available at the time of reading
- BI-RADS 1: negative
  - symmetrical and no masses, architectural distortion, or suspicious calcifications
- BI-RADS 2: benign
  - 0% probability of malignancy
- BI-RADS 3: probably benign
  - <2% probability of malignancy
  - short interval follow-up suggested
- BI-RADS 4: suspicious for malignancy
  - 2-94% probability of malignancy
  - biopsy should be considered
- BI-RADS 5: highly suggestive of malignancy
  - >95% probability of malignancy
  - appropriate action should be taken
- BI-RADS 6: known biopsy-proven malignancy

Breast Imaging Made Brief and Simple

- 0 Further information needed to put in assessment category
- 1 Normal
- 2 Benign finding
- 3 Probably benign-6 mo followup
- 4 Suspicious-biopsy
- 5 Malignant-biopsy

Breast composition

a- The breast are almost entirely fatty.

- Mammography is highly sensitive in this setting.

b- There are scattered areas of fibroglandular density.

- The term density describes the degree of x-ray attenuation of breast tissue but not discrete mammographic findings.

c- The breasts are heterogeneously dense, which may obscure small masses.

- Some areas in the breasts are sufficiently dense to obscure small masses.

d - The breasts are extremely dense, which lowers the sensitivity of mammography.

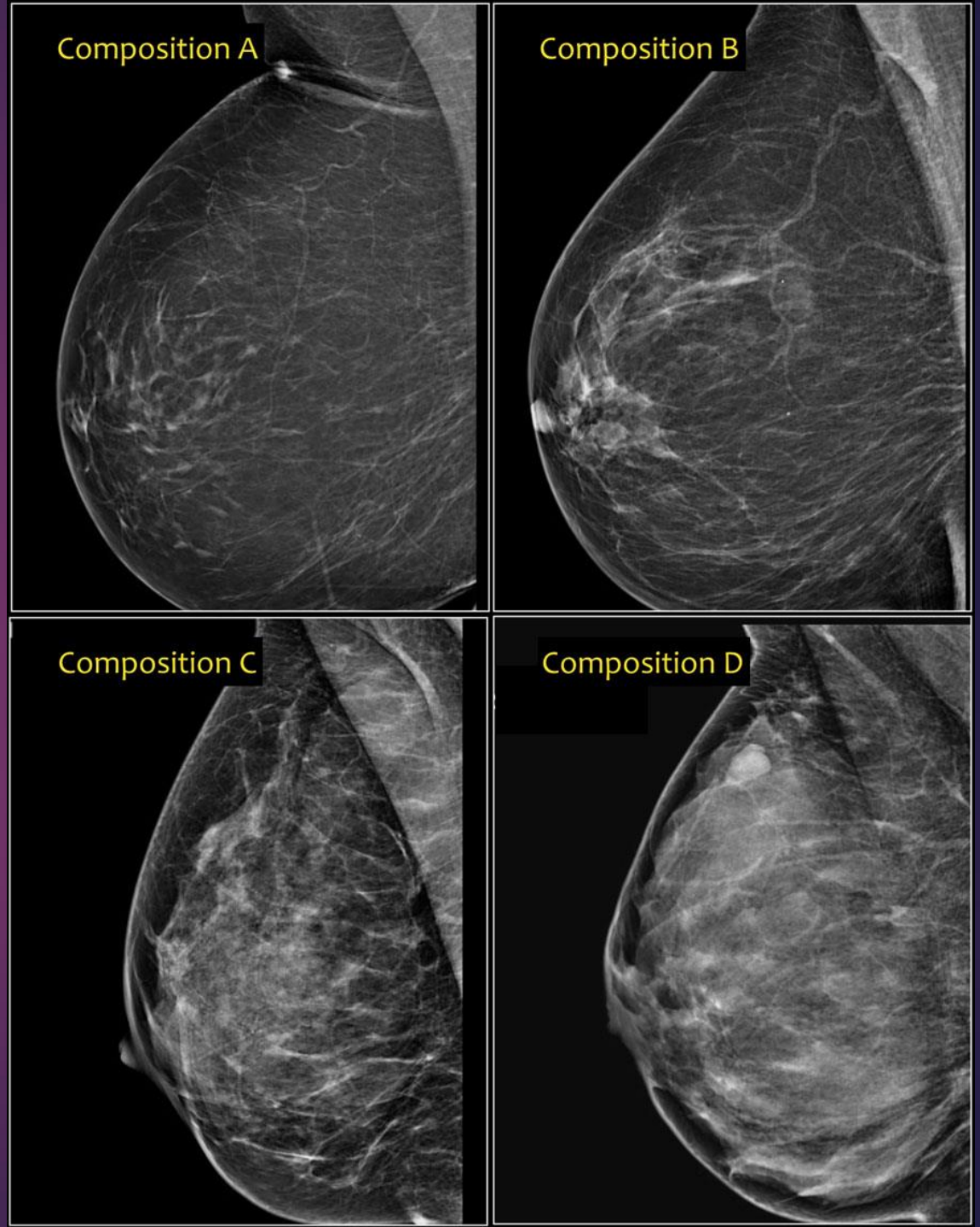

Breast Cancer Statistics

- Most common malignancy in American women (except skin)
- Approximately one third of new cancers diagnosed
- Second leading cause of death from cancer
- 211,300 new cases of invasive cancer this year
- 55,700 new cases of DCIS this year
- Leading cause of premature mortality- average 18.5 potential years of life lost

Breast Cancer Statistics

If breast cancer is diagnosed while the disease is local survival is 96%.

Survival for regional disease is 78%.

Survival for distant disease is 21%.

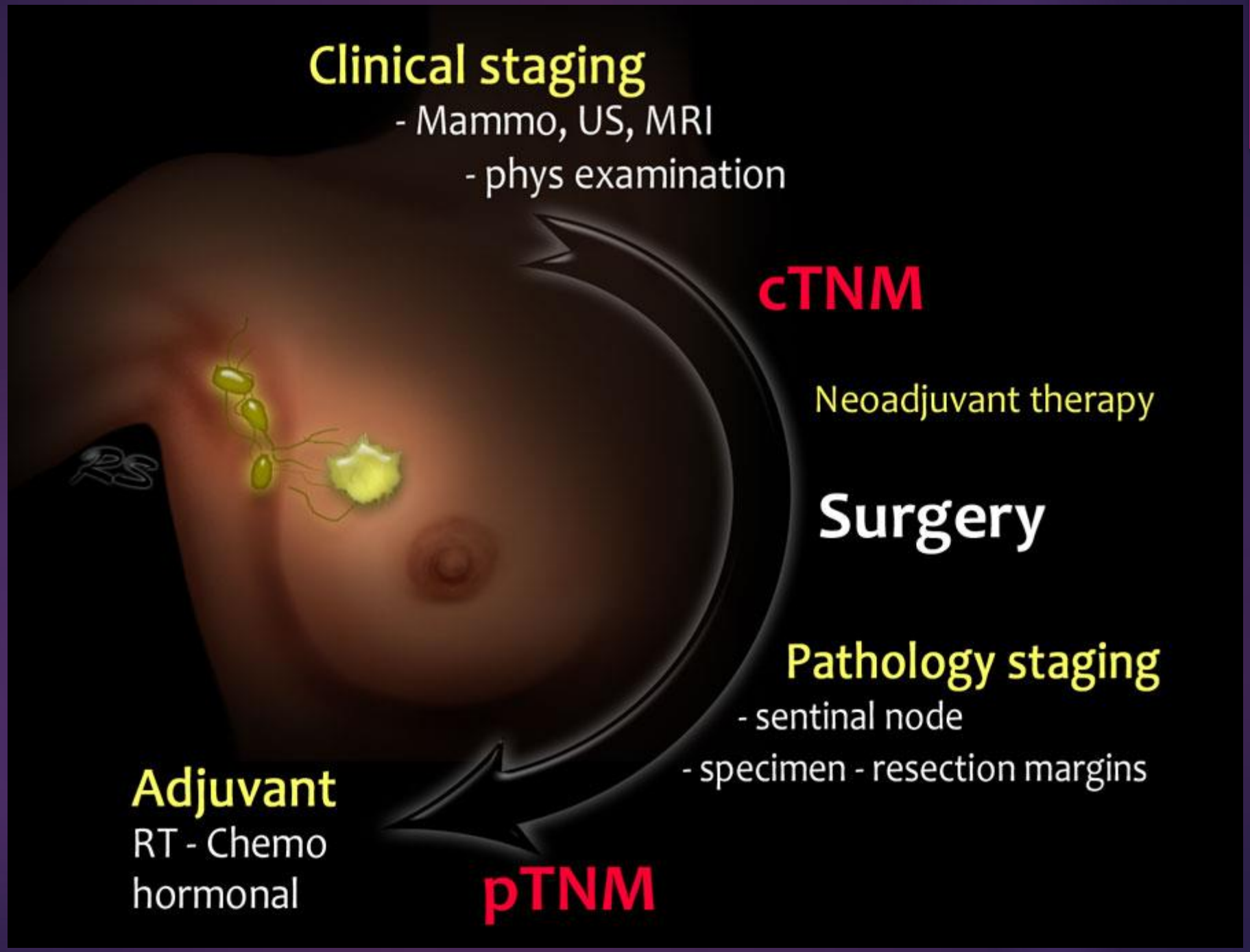
Clinical staging
- Mammo, US, MRI
- phys examination
cTNM
Neoadjuvant therapy
Surgery
Pathology staging
- sentinal node
- specimen - resection margins
Adjuvant
RT - Chemo
hormonal
pTNM

Methods of Detection of Breast Cancer

Breast Self Examination and Clinical Breast Examination are used in the women under 40 yo to detect palpable masses.

Methods of Detection of Breast Cancer

At 40 and older mammography is used to screen for breast cancer in women without symptoms.

Mammography is the most sensitive examination for detection of early breast cancers.

Risk factors for development of breast cancer

Female

Age > 35

Early menarche

Late menopause

Nulliparity

Pregnancy after 30

Affected first degree relative (mother, sister, daughter)

Previous history of breast cancer

Biopsy proof of atypical epithelial proliferation

Biopsy proof of lobular carcinoma in situ

Mammographic findings of breast cancer

Mass

Microcalcifications

Mass and microcalcifications

MASS

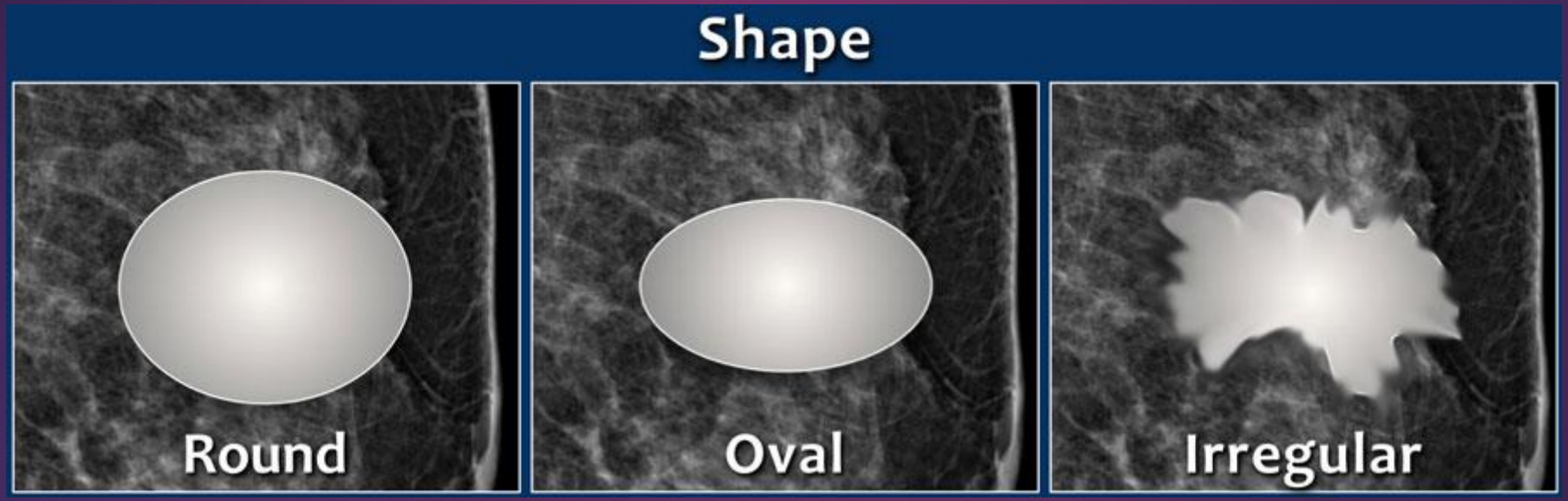

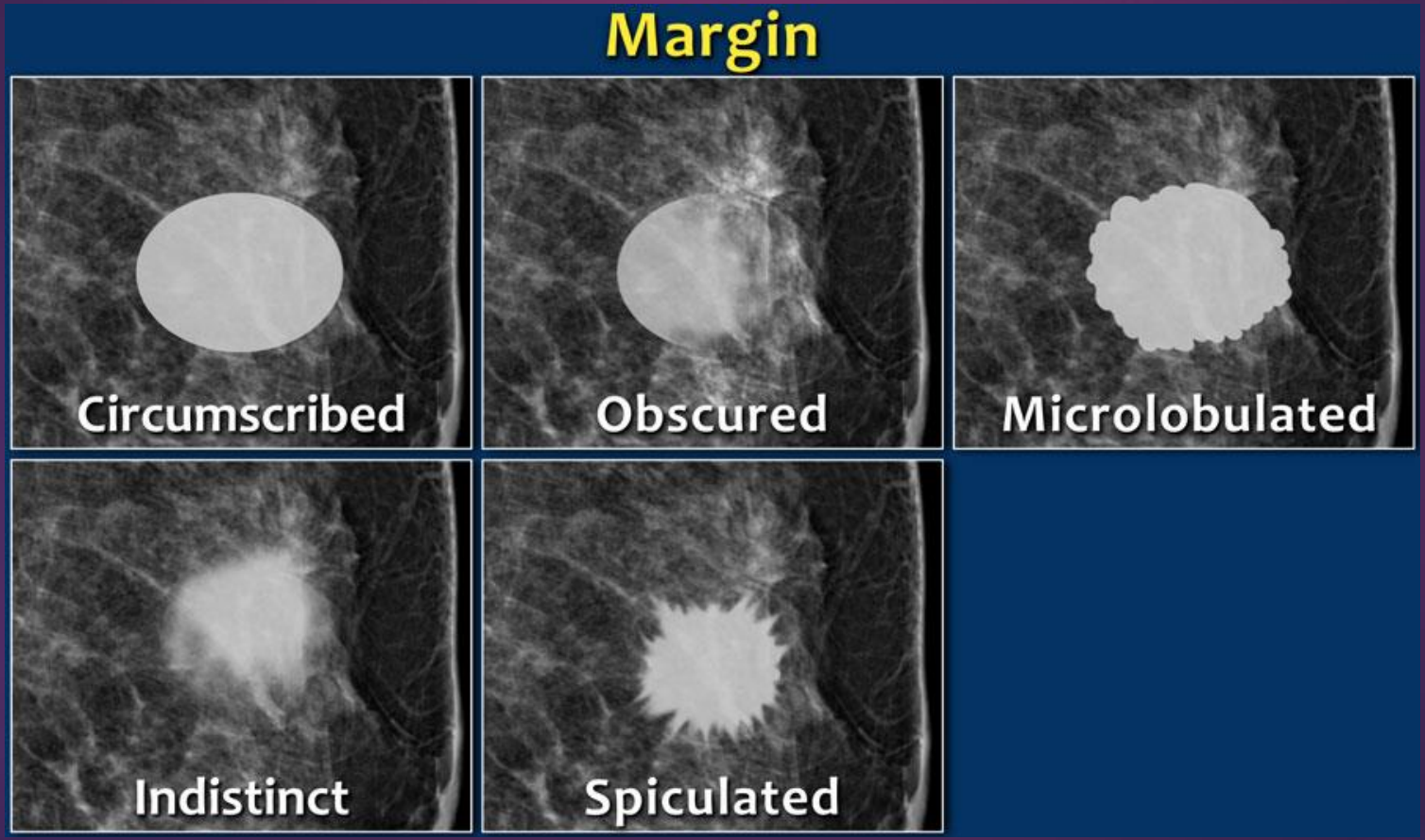
Margin
Circumscribed
Obscured
Microlobulated
Indistinct
Spiculated

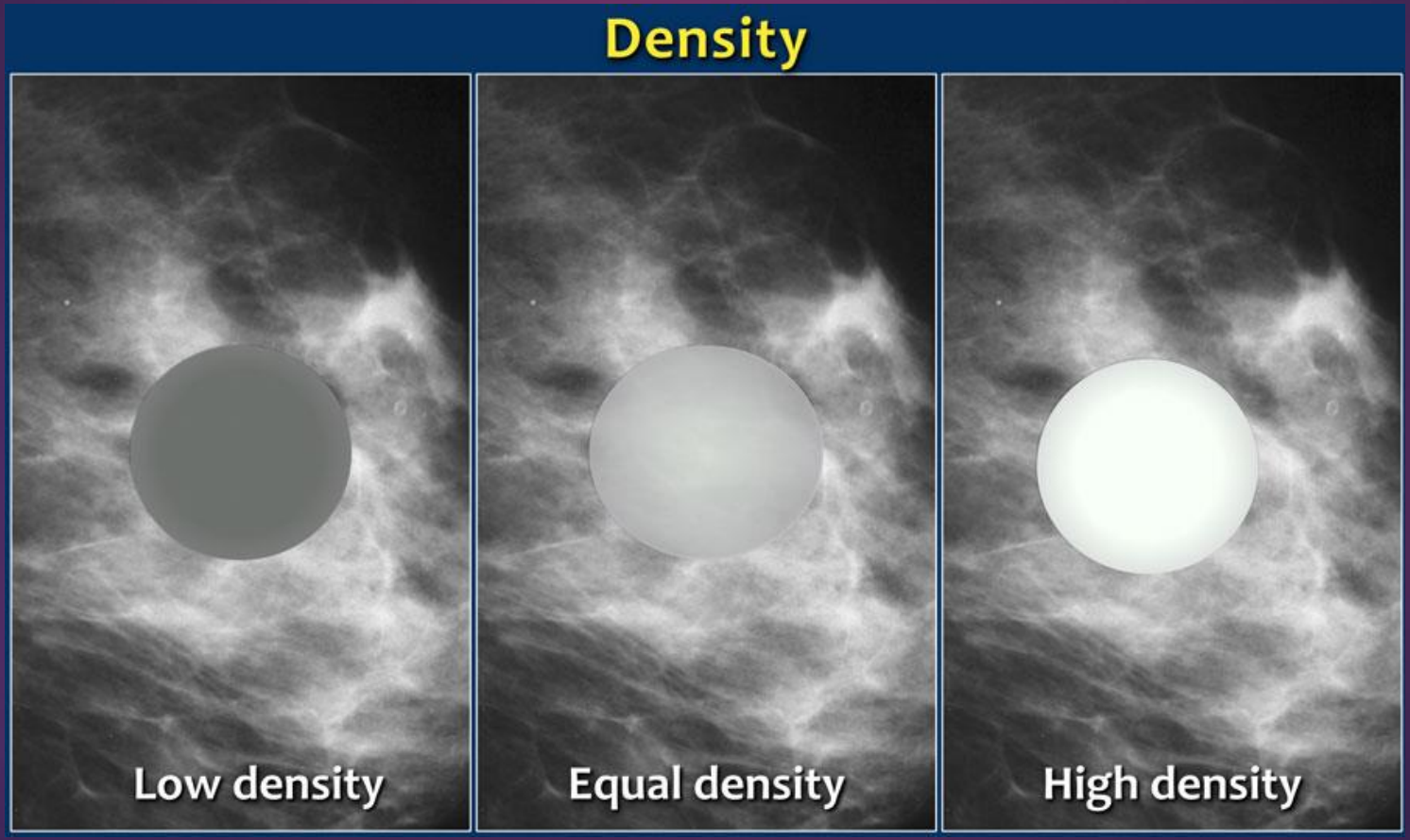
Density
Low density
Equal density
High density

Location

A mass is seen in the outer lower quadrant of the left breast at 4 o' clock in the posterior portion of the breast at 4cm distance from the nipple.
A mass is seen in the outer lower quadrant of the left breast at 4 o' clock in the posterior portion of the breast at 4cm distance from the nipple.

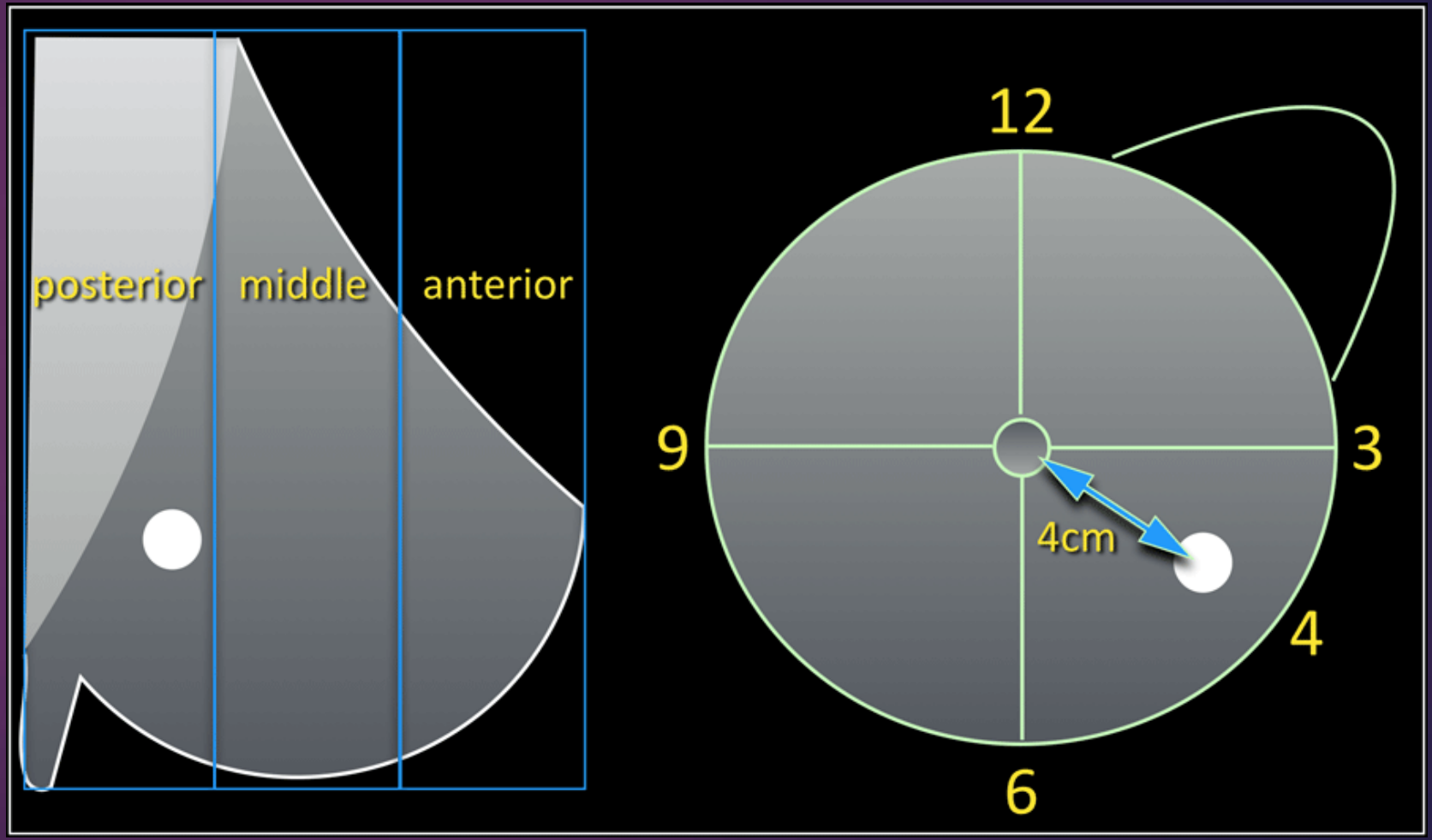

multiple round circumscribed low density masses in the right breast

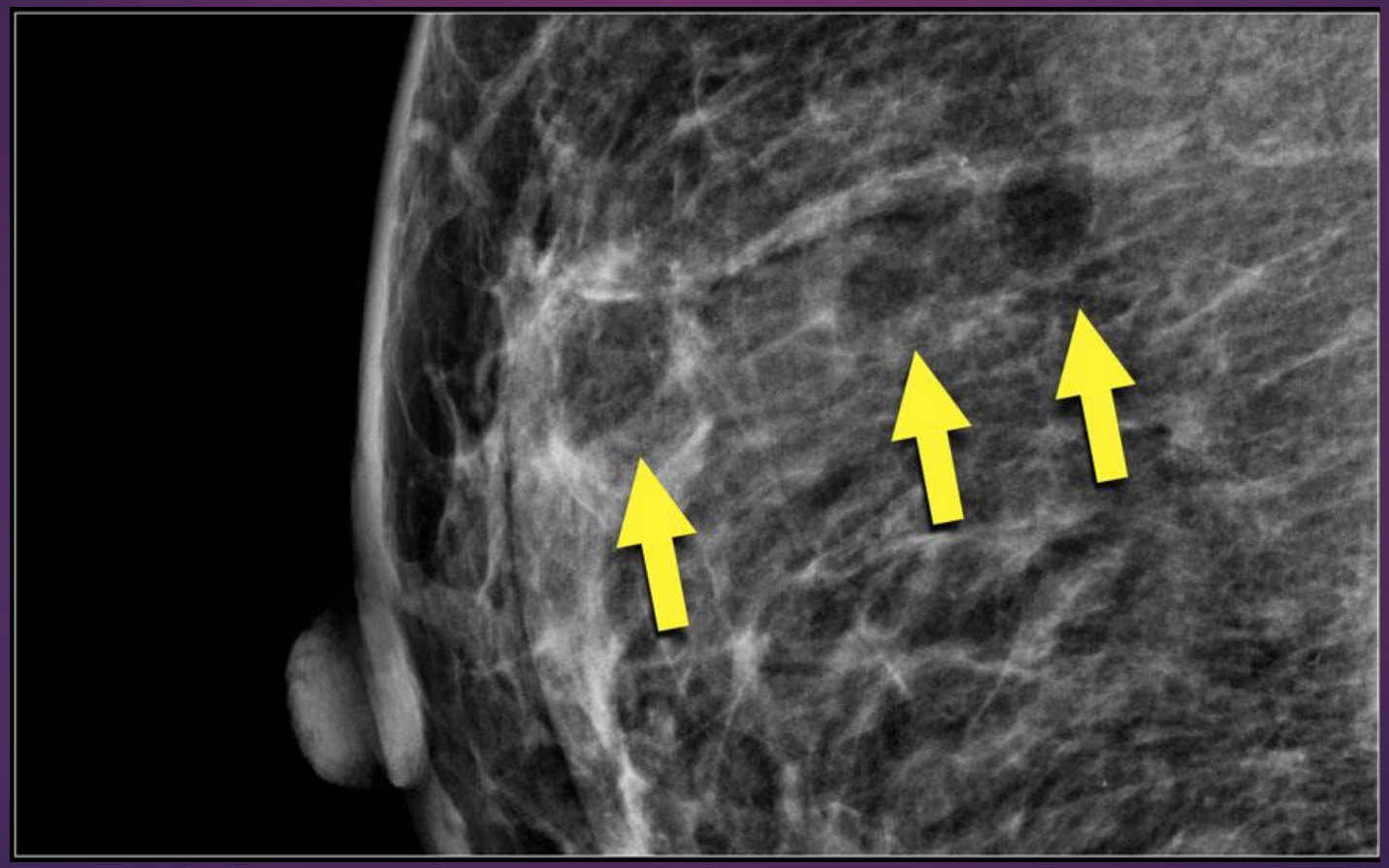

hyperdense mass with an irregular shape and a spiculated margin.
Notice the focal skin retraction

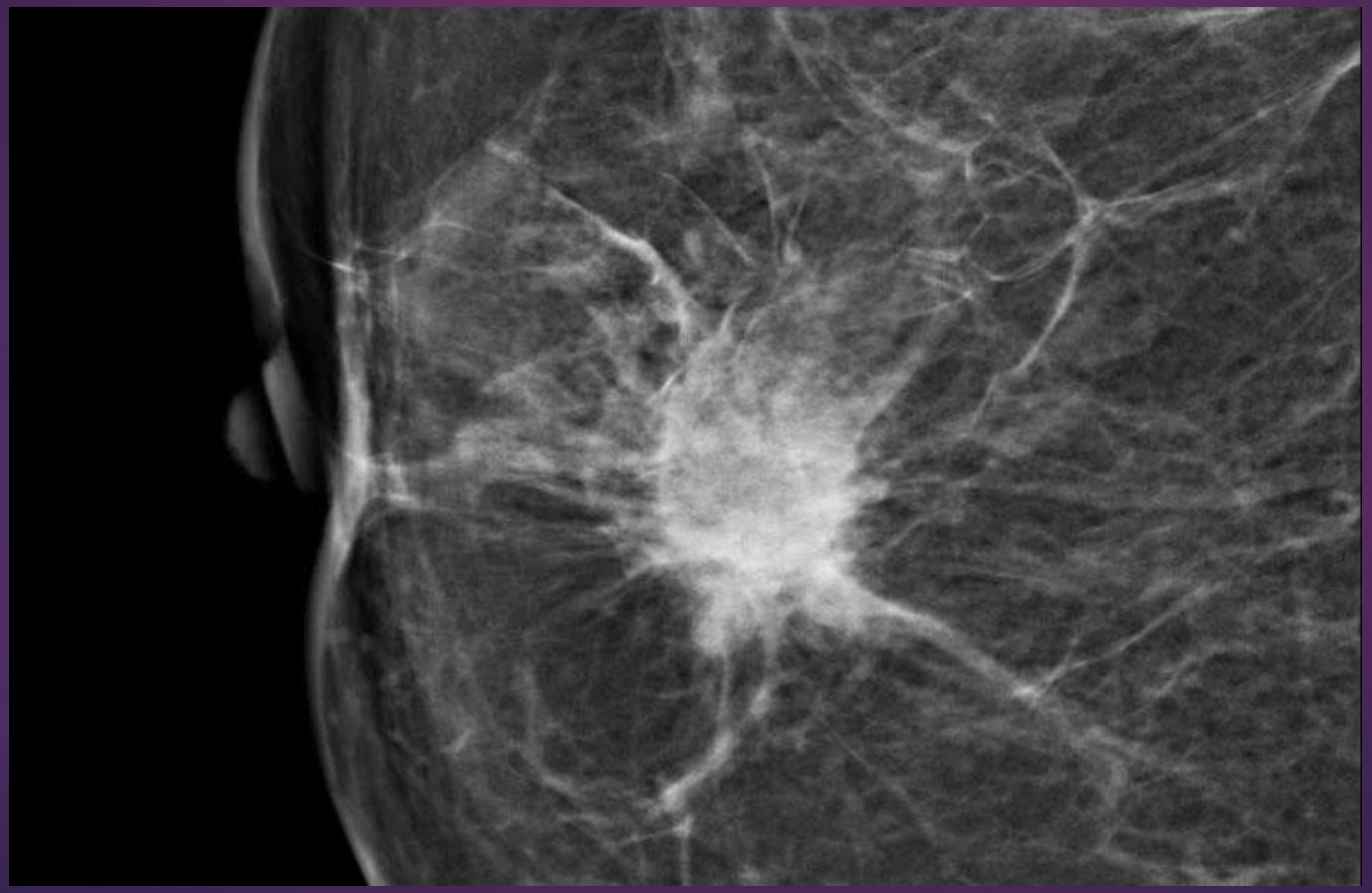

Mass

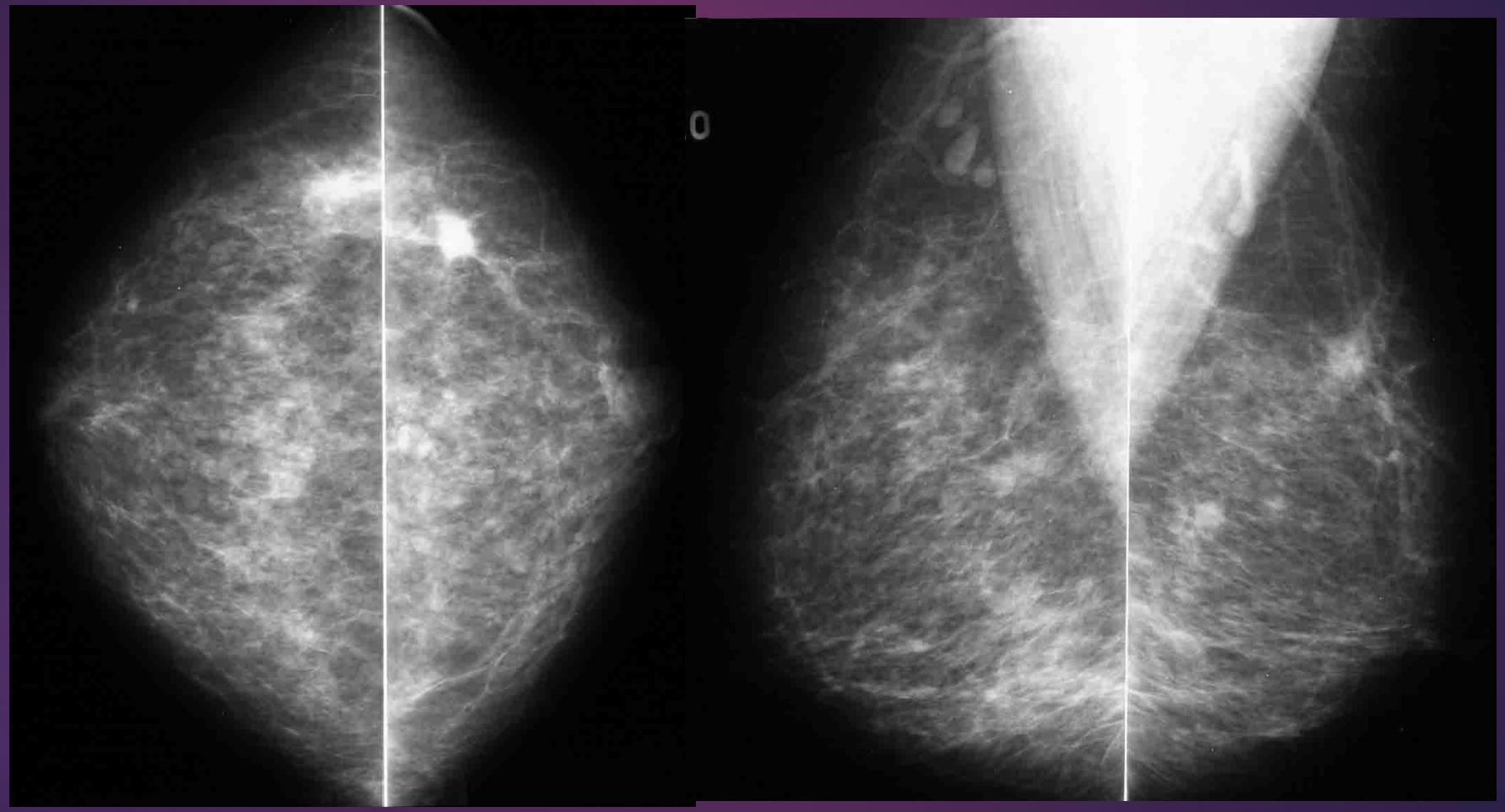

Asymptomatic screening mammogram

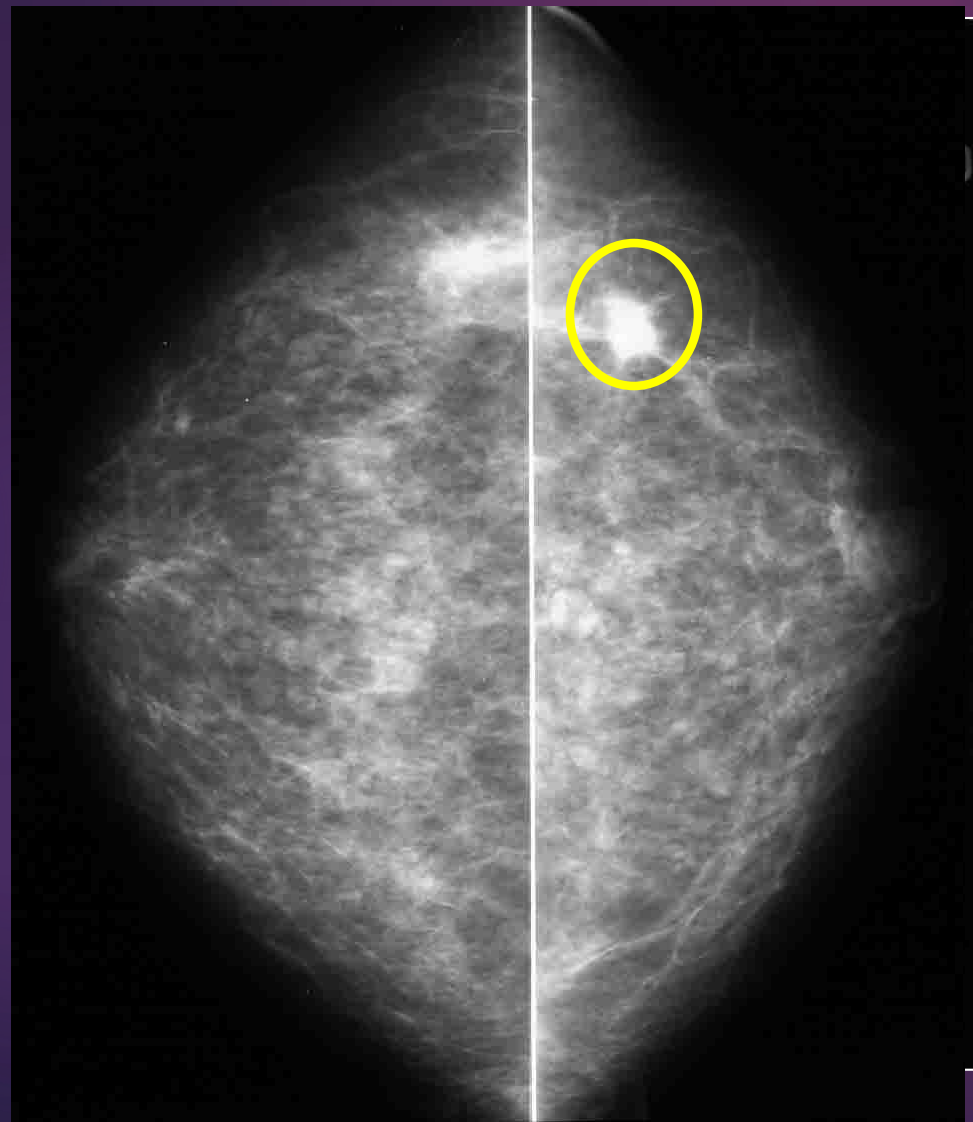

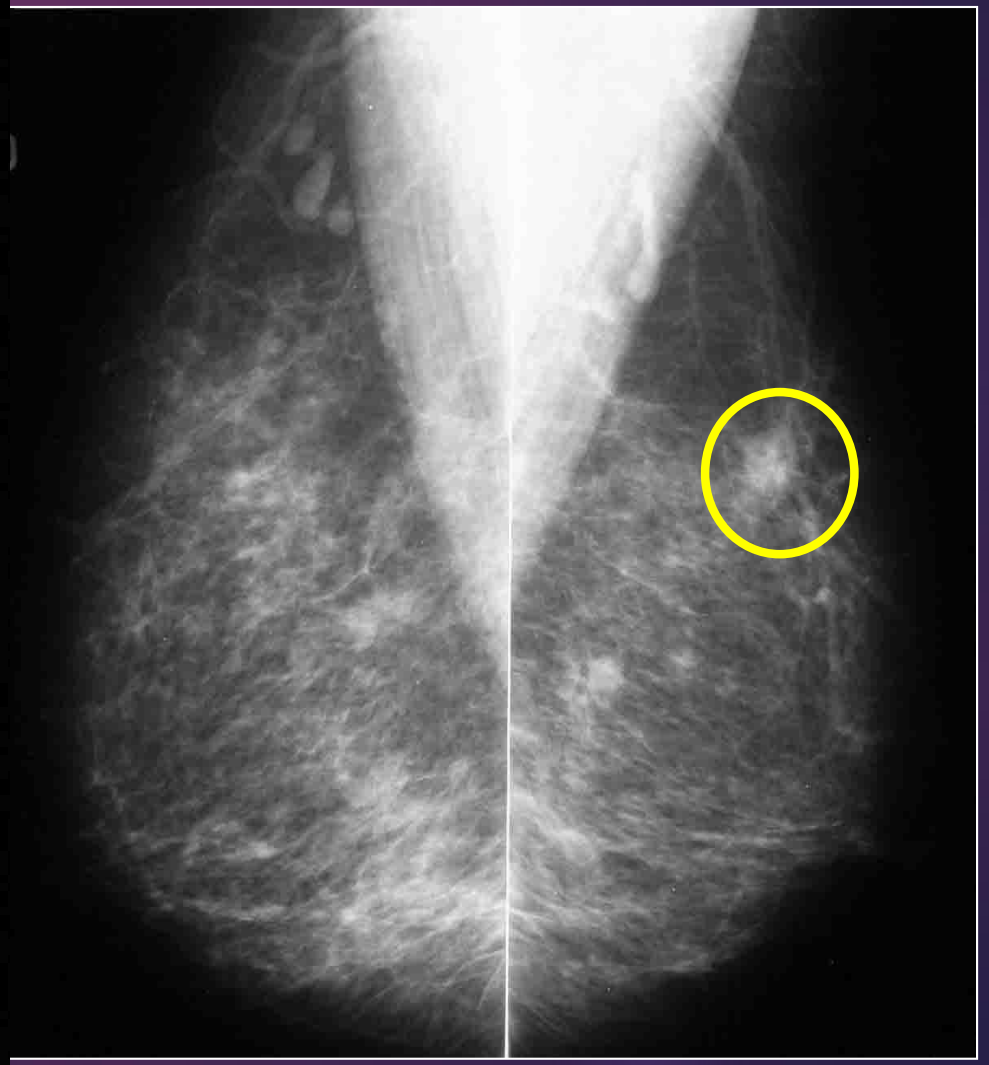

Architectural distortion

- when the normal architecture is distorted with no definite mass visible. This includes thin straight lines or spiculations radiating from a point, and focal retraction, distortion or straightening at the edges of the parenchyma.
  The differential diagnosis is scar tissue or carcinoma.

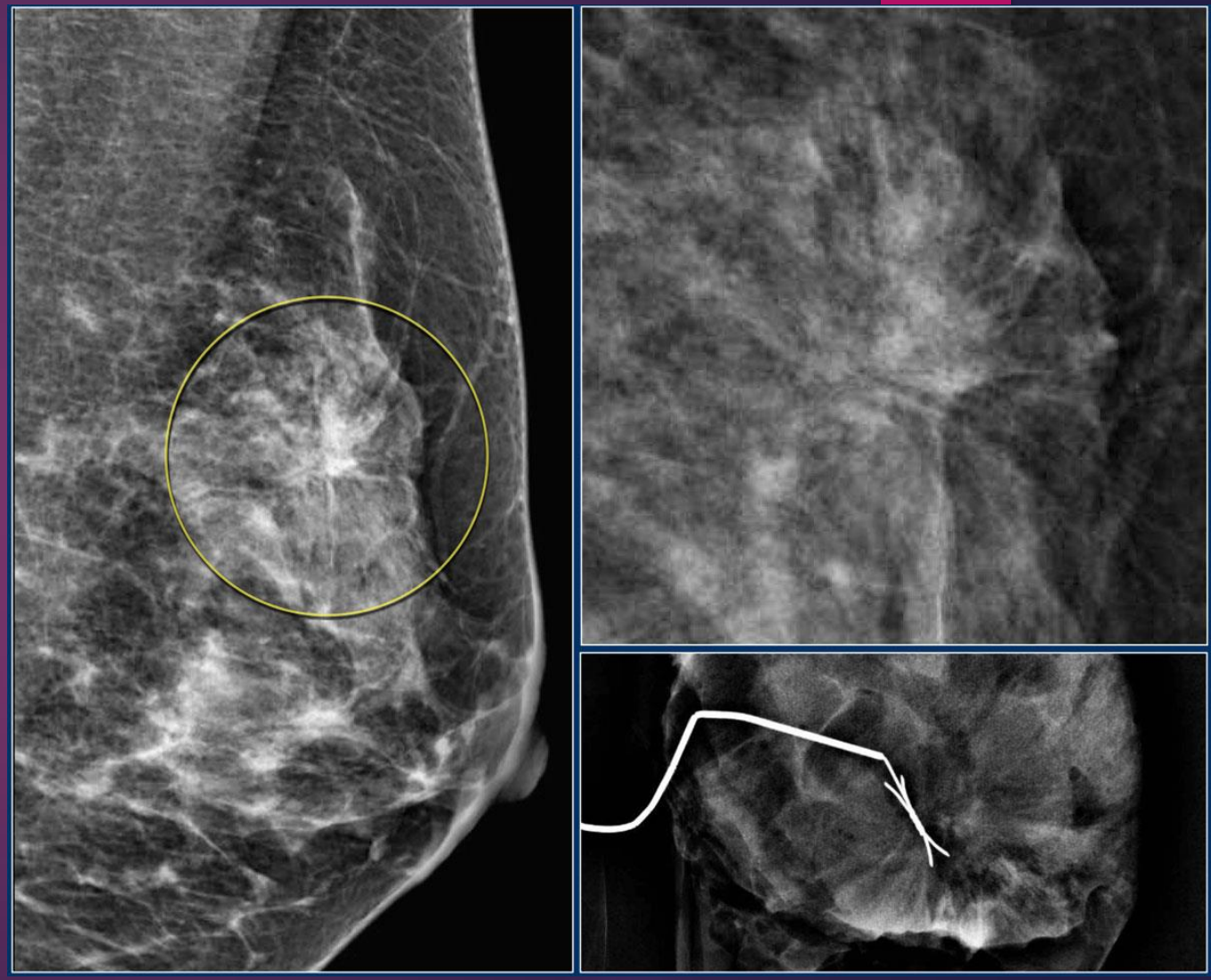

Calcification

- Most are benign and can be dismissed
- The goal is to identify new or increasing calcifications or those with suspicious morphology

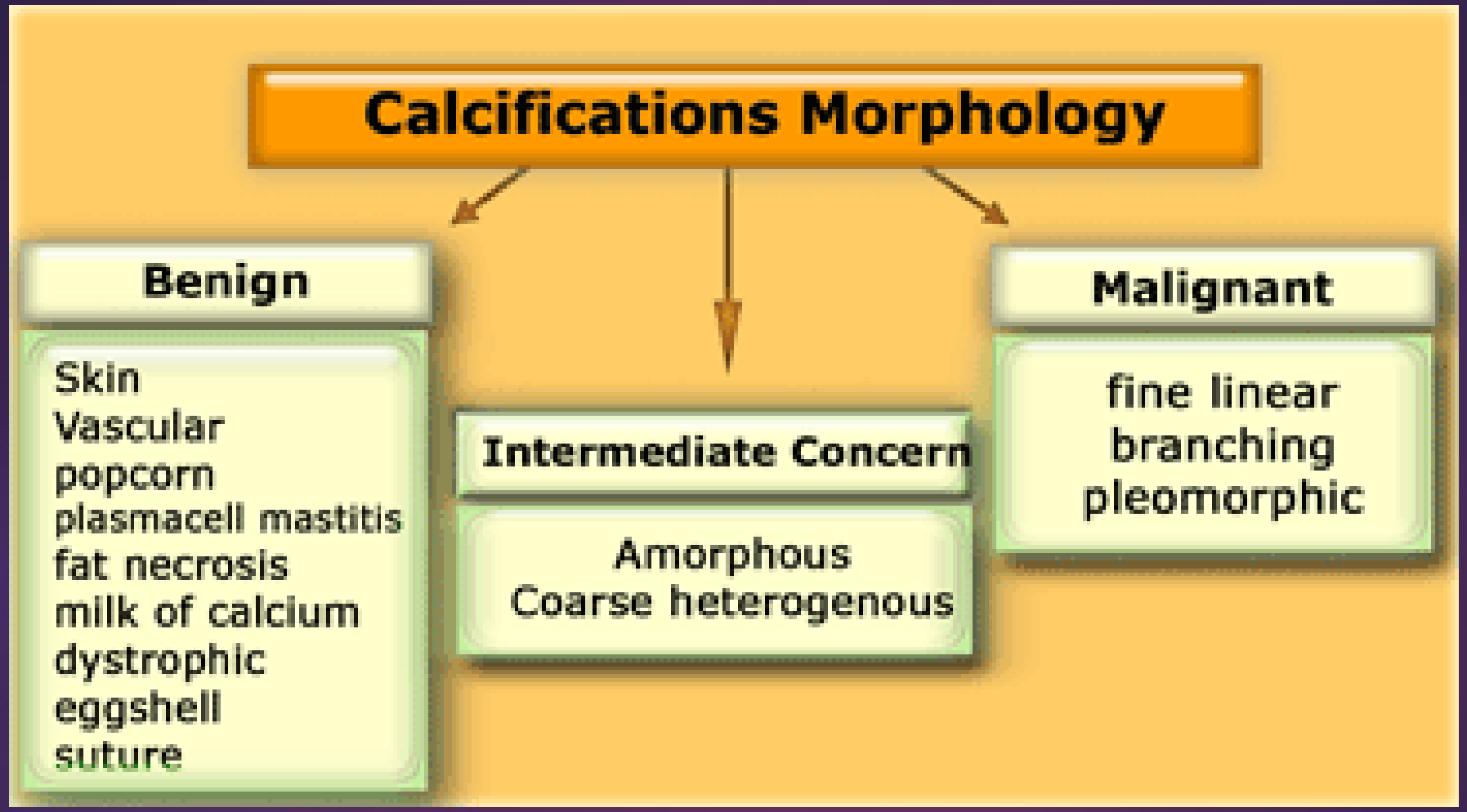
Calcifications Morphology
Benign
Skin
Vascular
popcorn
plasmacell mastitis
fat necrosis
milk of calcium
dystrophic
eggshell
suture
Intermediate Concern
Amorphous
Coarse heterogenous
Malignant
fine linear
branching
pleomorphic

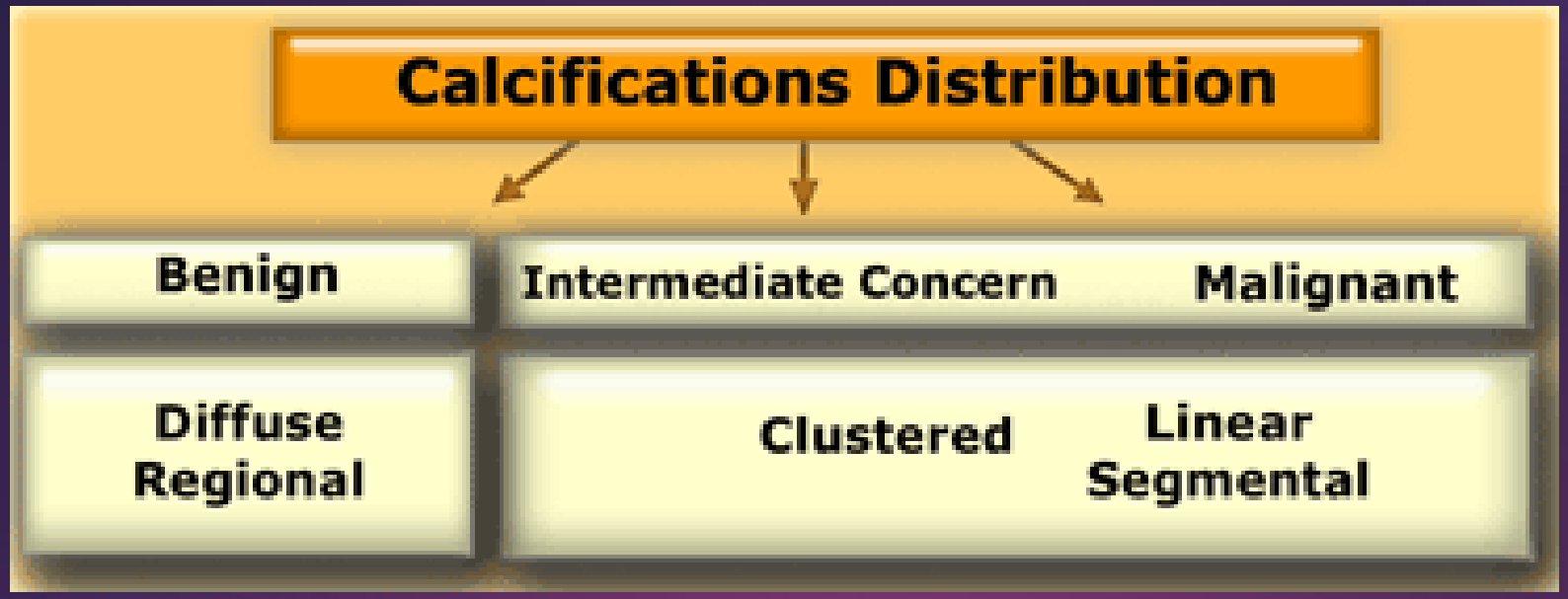
Calcifications Distribution
Benign
Intermediate Concern
Malignant
Diffuse
Regional
Clustered
Linear
Segmental

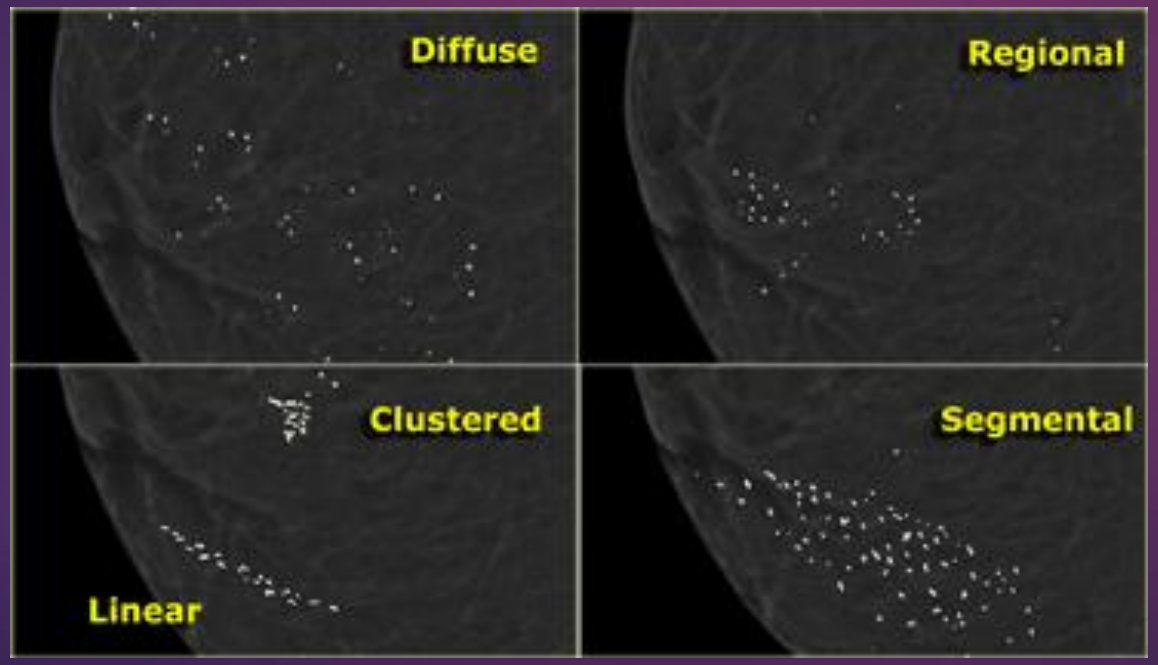
Diffuse
Regional
Clustered
Segmental
Linear

Typically Benign

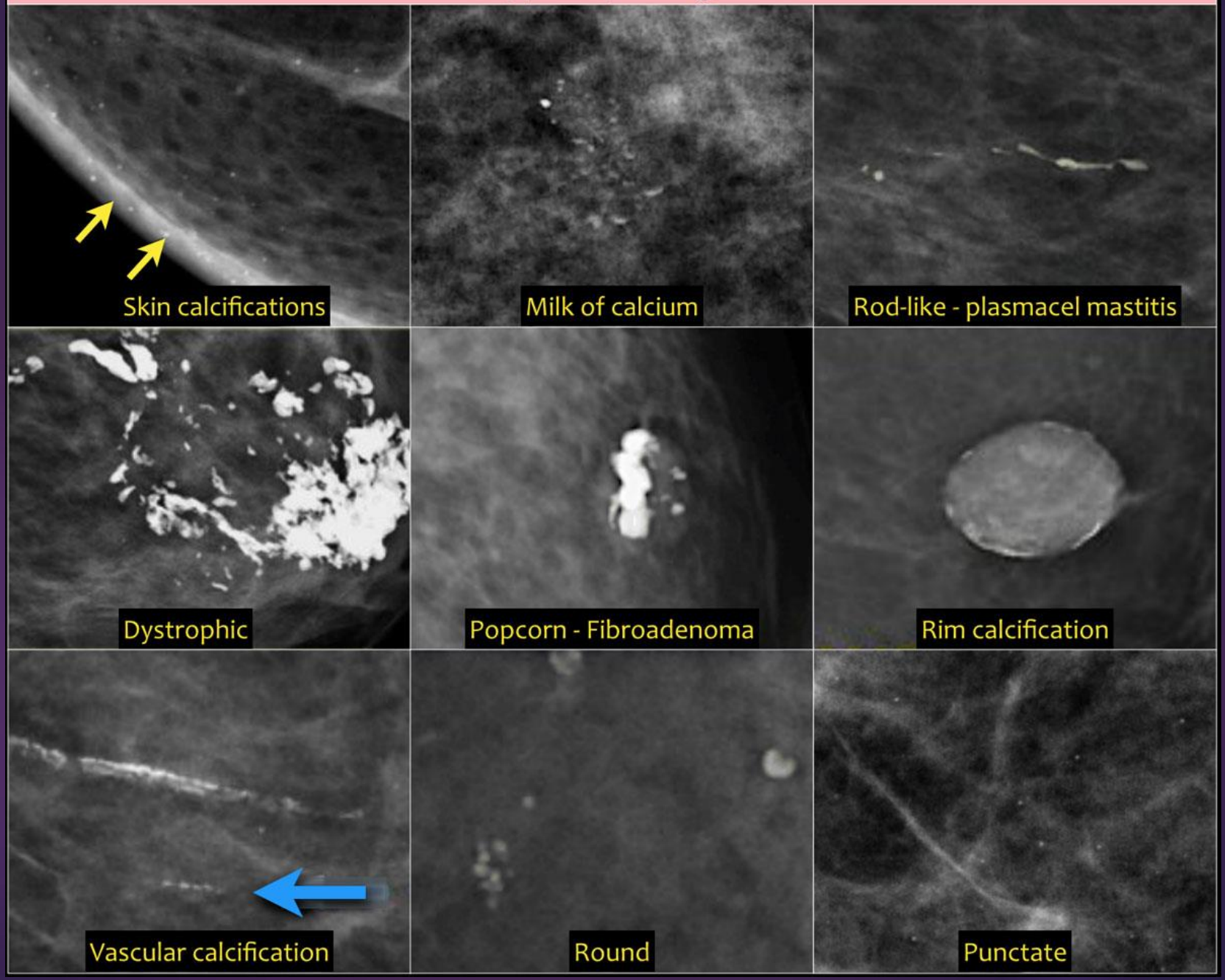

Suspicious morphology

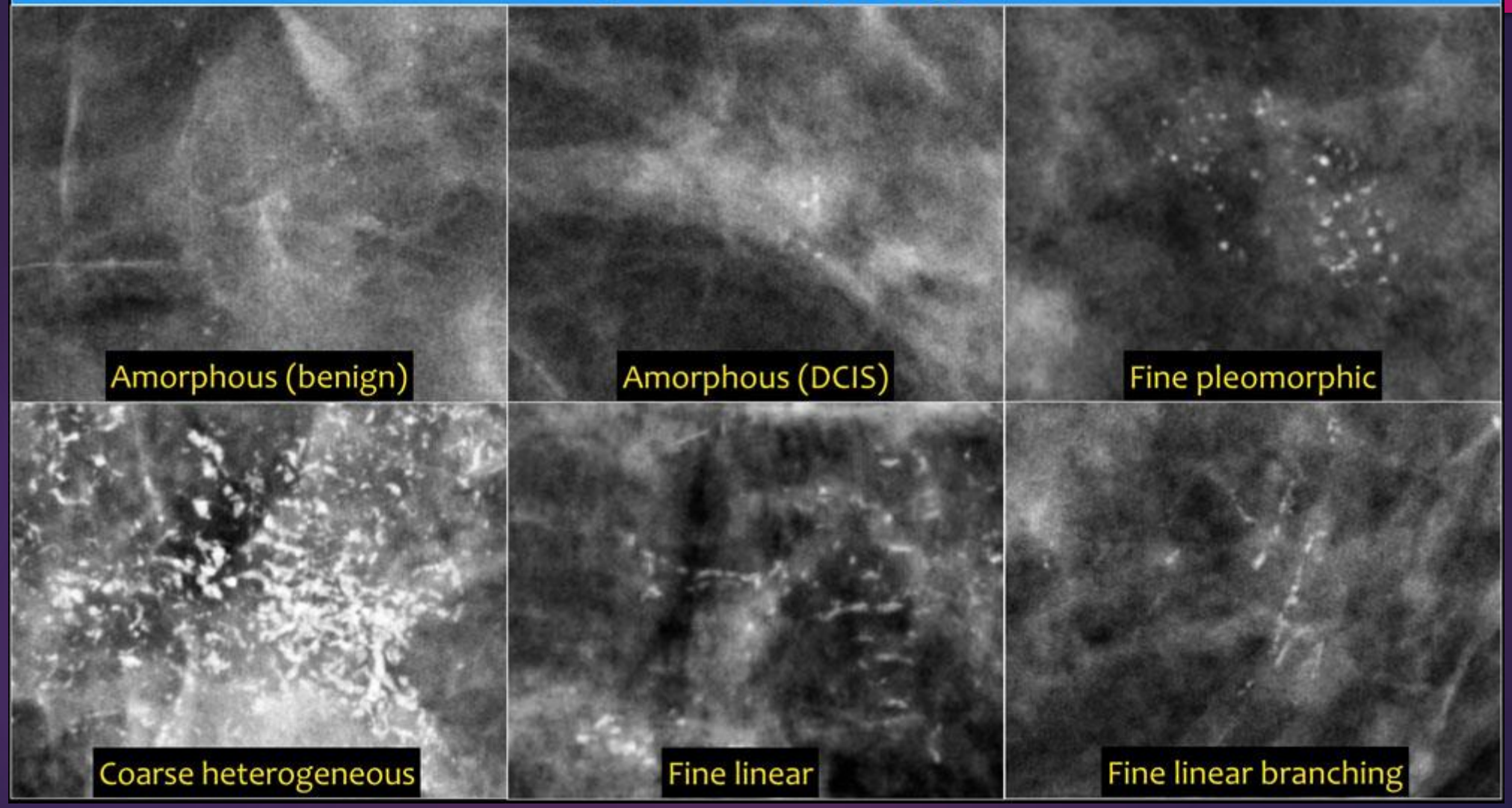

Malignant microcalcification

- Linear, branching casts – comedo
- Granular/ irregular – crushed stone
- Punctate - powdery

Microcalcifications

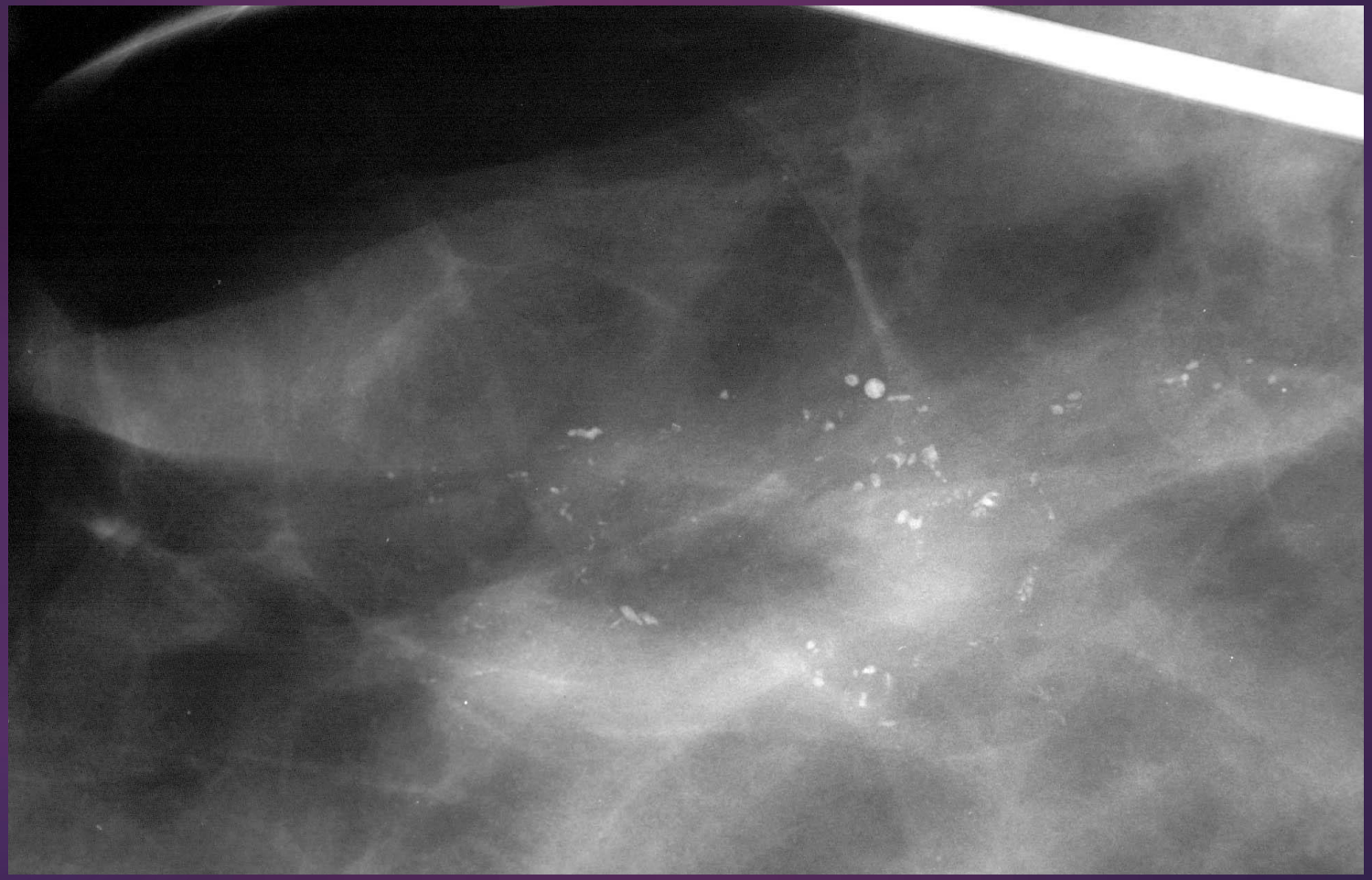

Standard Reporting

1. Indication
2. Breast Composition → Composition: a-b-c-d
3. Important findings → Mass, Asymmetry, Architectural distortion, Calcifications, Associated features
4. Comparison to previous studies

5. Final Assessment Category

6. Give management recommendations
7. Communicate unsuspected findings with the referring clinician

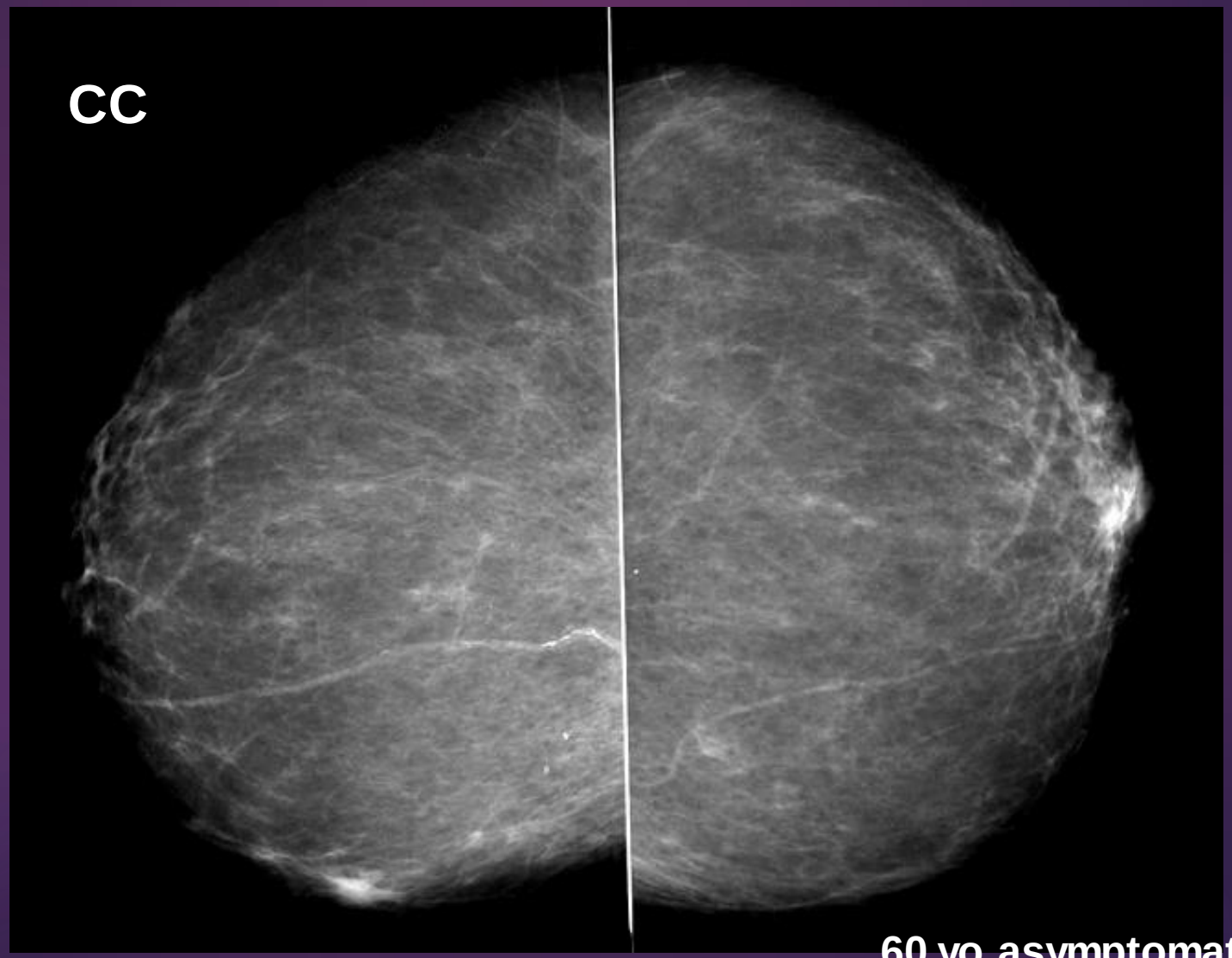

60 yo asymptomatic

MLO

60 yo asymptomatic

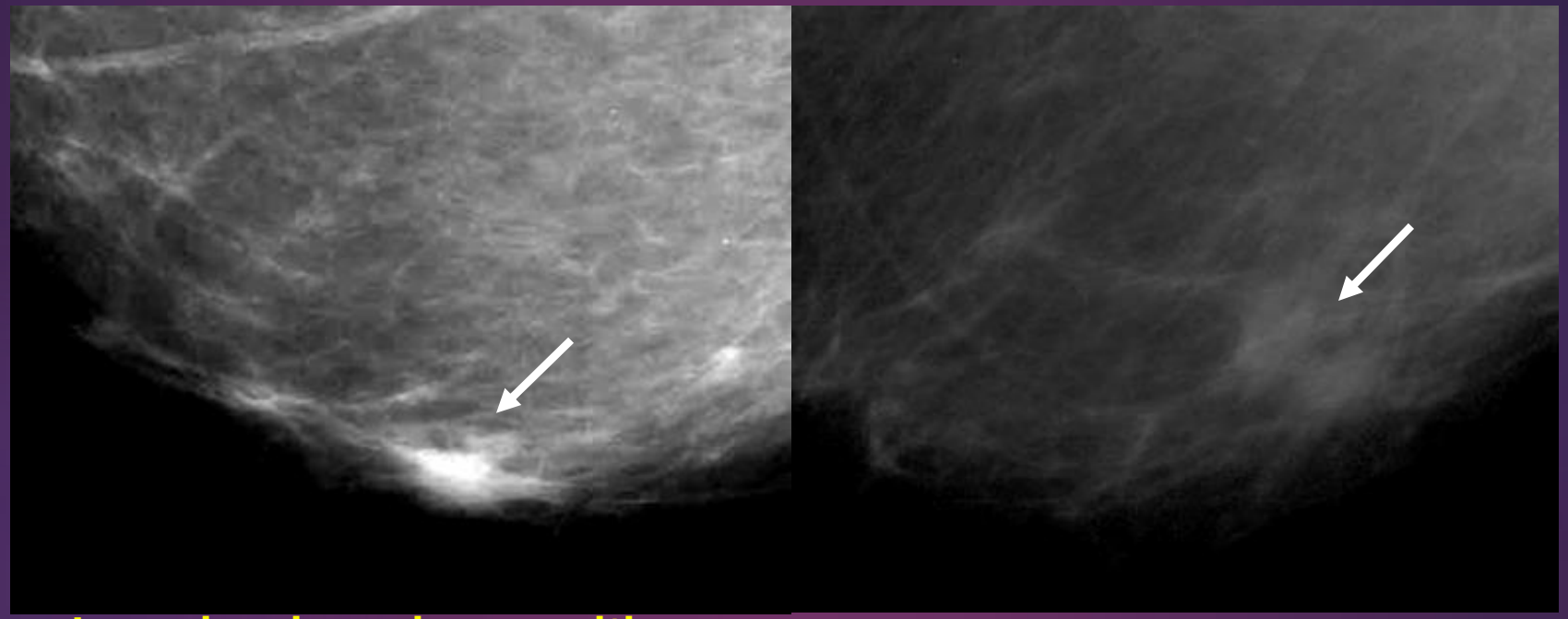

Irregular shaped mass with indistinct margins on the left at 8:00 in the middepth of the breast

BI-RADS 4 Biopsy recommended

Dx: Invasive ductal carcinoma

The women with symptoms have a diagnostic mammogram first. Symptoms usually include a palpable mass or nipple discharge.

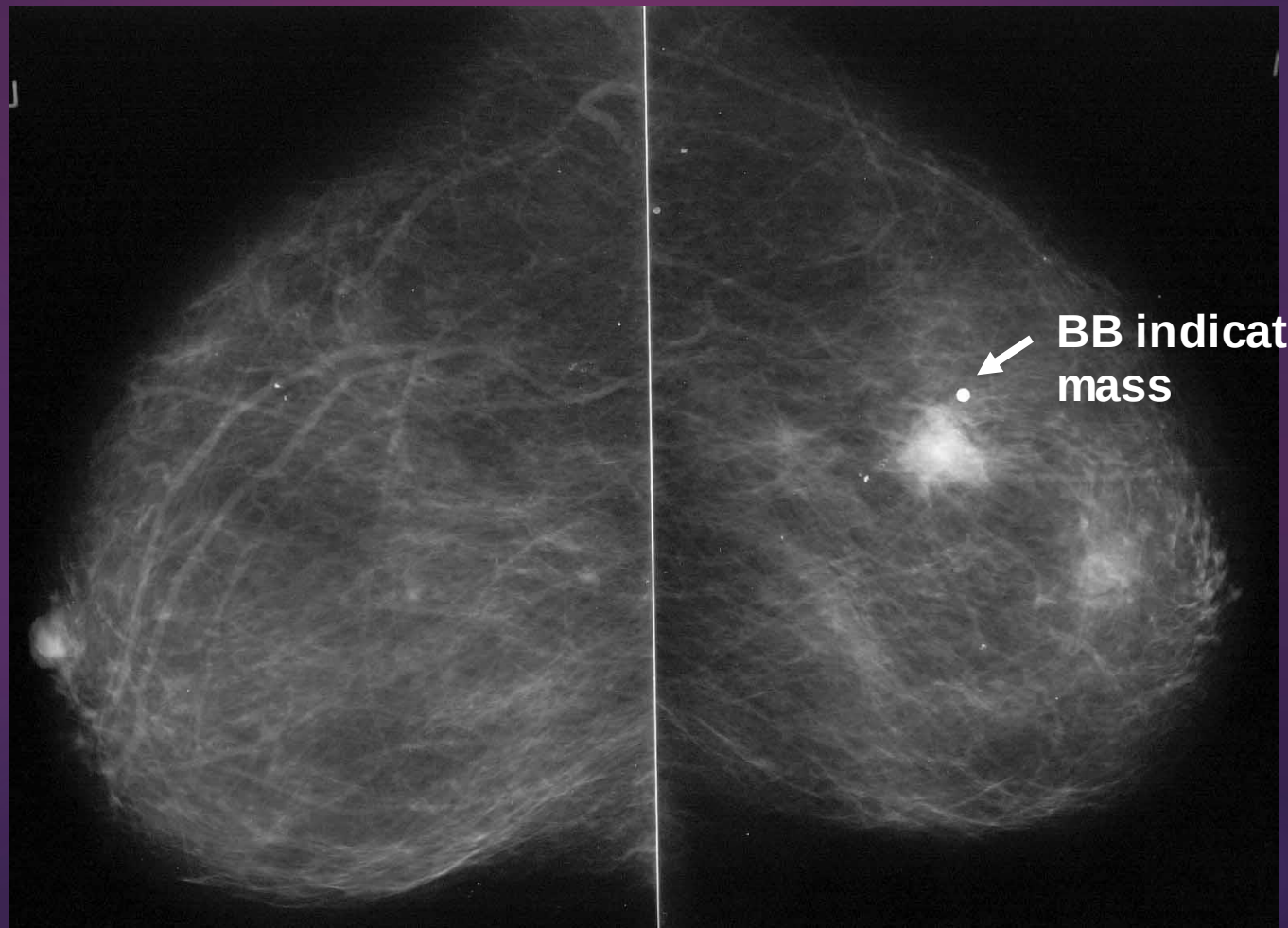
BB indicating palpable mass

Further imaging workup for these women includes additional mammographic views and ultrasound.

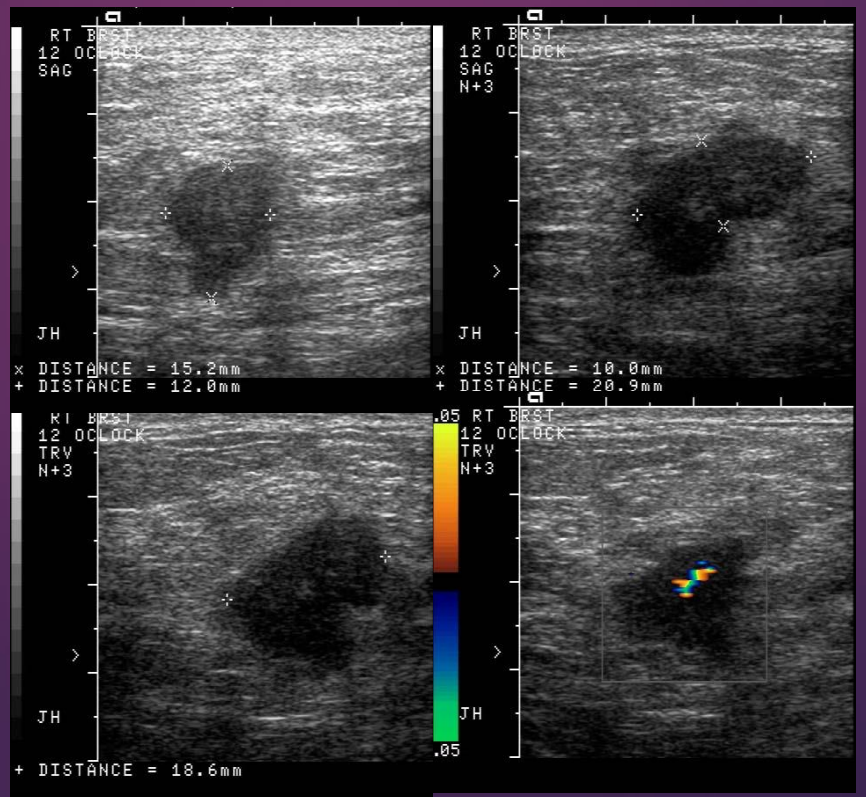

DCIS

- Ductal carcinoma in situ is the most common non-invasive breast cancer.
- In situ means 'in place' and refers to the fact that the cancer has not moved out of the duct and does not infiltrate the surrounding tissue.
- DCIS can progress to become invasive cancer, but likelihood estimates vary.
- 80% of DCIS is diagnosed on mammography alone on the basis of microcalcifications (figure), followed by vacuum-assisted biopsy. Very few cases of DCIS present as a palpable mass.

There are multiple fine, linear calcifications in a large segment of the breast. These are suspicious calcifications and are typically seen in DCIS.

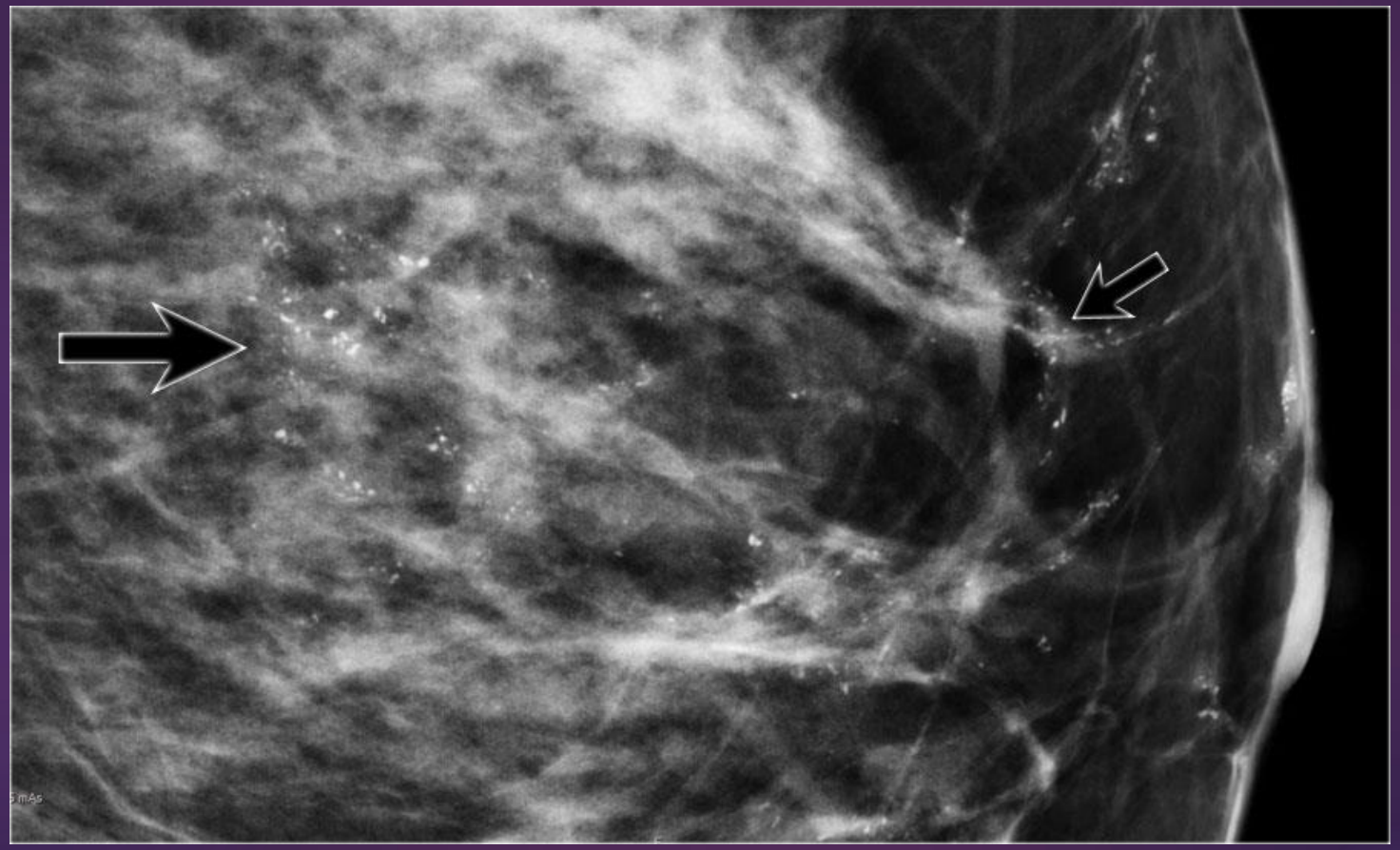

LIMITATIONS OF MAMMOGRAPHY

- As many as 5 – 15% of breast cancers are not detected mammographically
- A negative mammogram should not deter work-up of a clinically suspicious abnormality

FALSE NEGATIVES

- Causes
  - Occult on mammogram (lobular CA)
  - Finding obscured by dense tissue
  - Technical
  - Error of interpretation

RISK OF MAMMOGRAPHY

- Average glandular dose from a screening mammogram is extremely low
- Comparable risks are:
  - Traveling 4000 miles by air
  - Traveling 600 miles by car
  - 15 minutes of mountain climbing
  - Smoking 8 cigarettes

Breast MRI

- Magnetic resonance imaging is used :
  - For problem solving
  - For assessing the extent of lobular or extensive cancers
  - For screening high risk women - high risk family history and women who have had mantle radiotherapy for Hodgkins' disease
  - Pre and post neoadjuvant chemotherapy
  - For women with implants, to assess integrity

Detecting cancers on MRI

- Dynamic scan – bolus injection of Gadolinium and rapid sequence of images
- Benign lesions can enhance
- Need to create a graph showing pattern of uptake over time
- Cancers show rapid uptake and washout

THANK YOU!